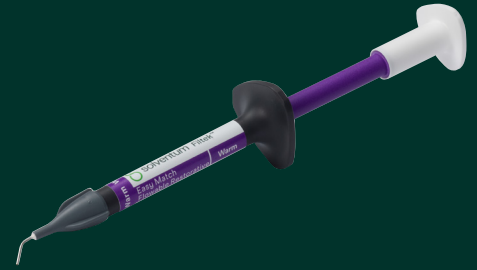


# Injection molding technique in direct veneers with Solventum™ Filtek™ Easy Match Flowable Restorative



Clinical case

Dr. Cristiano Bonacina

## About the case

60-year-old male patient showing progressive signs of wear on the lower incisors. Dr. Bonacina decided to proceed with direct veneer restorations using the injection molding technique.

## Challenge

One of the main challenges in injection molding cases with diastemas is the management of the emergence profiles. It is essential to create correct contours and properly polish the interproximal areas to allow effective and adequate oral hygiene.

## Outcome

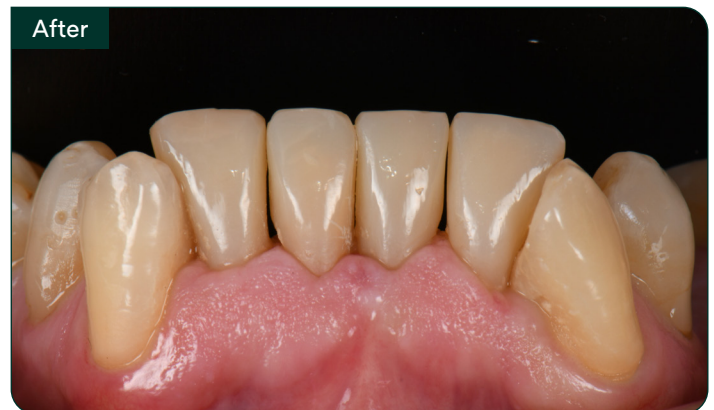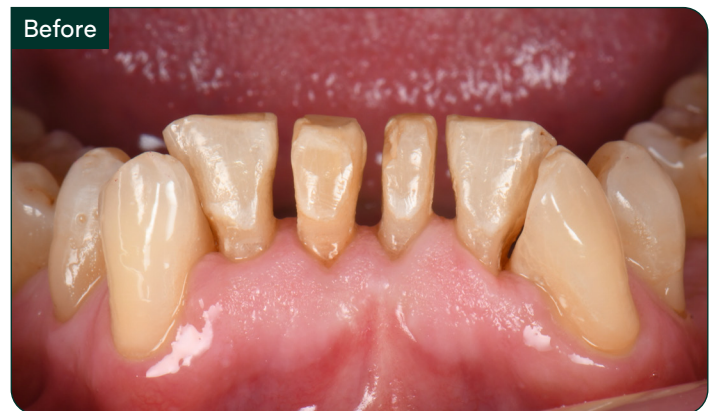Solventum™ Filtek™ Easy Match Flowable Restorative has excellent shade blending properties, even in full-thickness restorations. This flowable composite provides appropriate optical properties, enabling natural-looking results, even with a single-shade technique, and offers excellent polishability.

### Featured products:

Solventum™ Filtek™ Easy Match Flowable Restorative

Warm shade

3M™ Scotchbond™ Universal Plus Adhesive

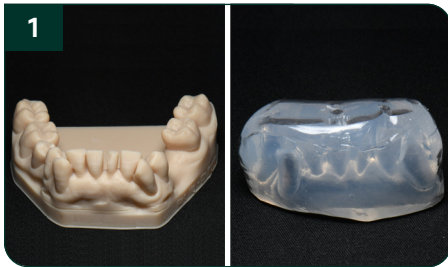

### About Dr. Cristiano Bonacina

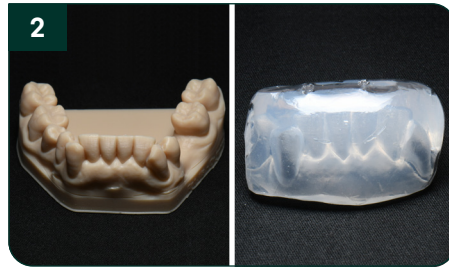Cristiano Bonacina graduated in 2016 from the University of Milan-Bicocca (Italy) with a degree in Dentistry & Dental Prosthetics. He continued his postgraduate studies, achieving a Master Course in Clinical Periodontology & Implant Dentistry under Prof. Zucchelli at the Alma Mater Studiorum University in Bologna (Italy) in 2021, and a Master Course in Forensic Odontology at the University of Florence (Italy) in 2023. He is a general practitioner, mainly focused on adhesive esthetic dentistry, implantology and periodontology. He primarily works in his private practice in Veduggio con Colzano, MB (Italy).

# Case overview

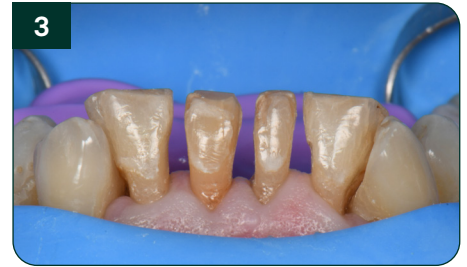Refer to instructions for use (IFU) for complete product information.



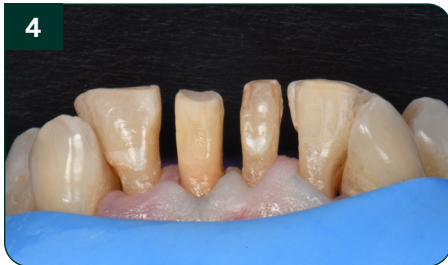Resin-printed model of the wax-up for the first silicone matrix for injection of teeth 32 and 41.



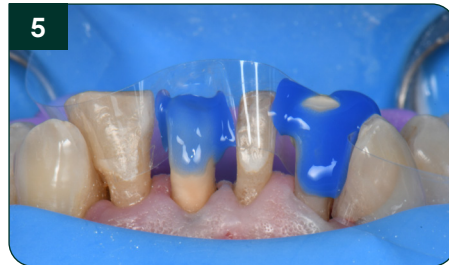Resin-printed model of the wax-up for the second silicone matrix for injection of teeth 31 and 42.



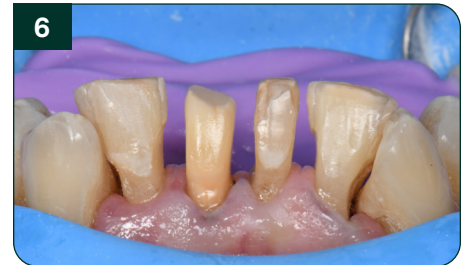Isolation with split rubber dam.



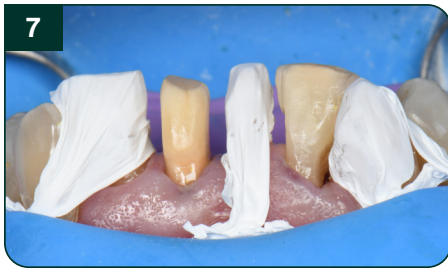Minimally invasive buccal preparation of teeth 41 and 32 to provide a minimum thickness of approximately 0.5–0.7 mm.



Protection of teeth 41 and 32 with mylar strip matrix, placement of a retraction cord and enamel etching for 15 seconds.



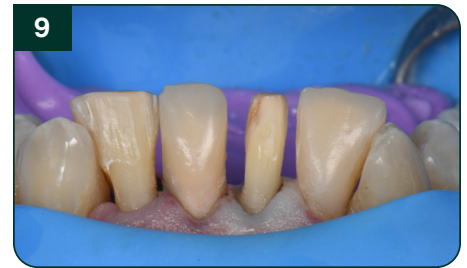Application and light-curing of 3M<sup>™</sup> Scotchbond<sup>™</sup> Universal Plus Adhesive.



Placement of PTFE tape on teeth adjacent to those being injected.



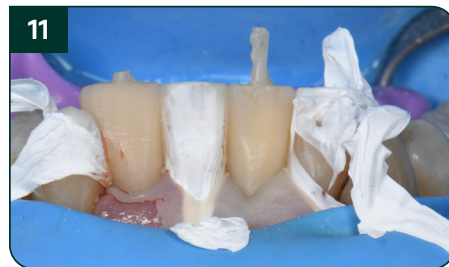Seating of the first silicone matrix and injection with Solventum<sup>™</sup> Filtek<sup>™</sup> Easy Match Flowable Warm shade, followed by light-cure.



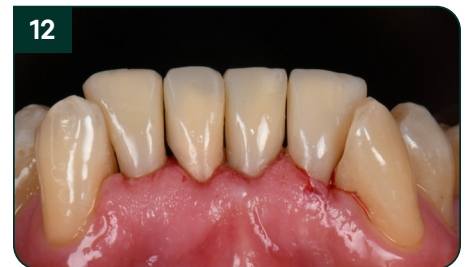Removal of the first silicone matrix, followed by careful finishing and polishing. Same procedure is followed for 42 and 31.



Seating of the second silicone matrix and injection of teeth 42 and 31 with Solventum<sup>™</sup> Filtek<sup>™</sup> Easy Match Flowable Warm shade, followed by polymerization.



Clinical situation after removal of the second silicone matrix.



Immediate post-operative buccal view after finishing and polishing.



Solventum Dental Solutions

1-800-634-2249  
Solventum.com

[Learn more at Solventum.com](https://www.solventum.com)

© Solventum 2026. Solventum, the S logo and Filtek are trademarks of Solventum or its affiliates. 3M and Scotchbond are trademarks of 3M.