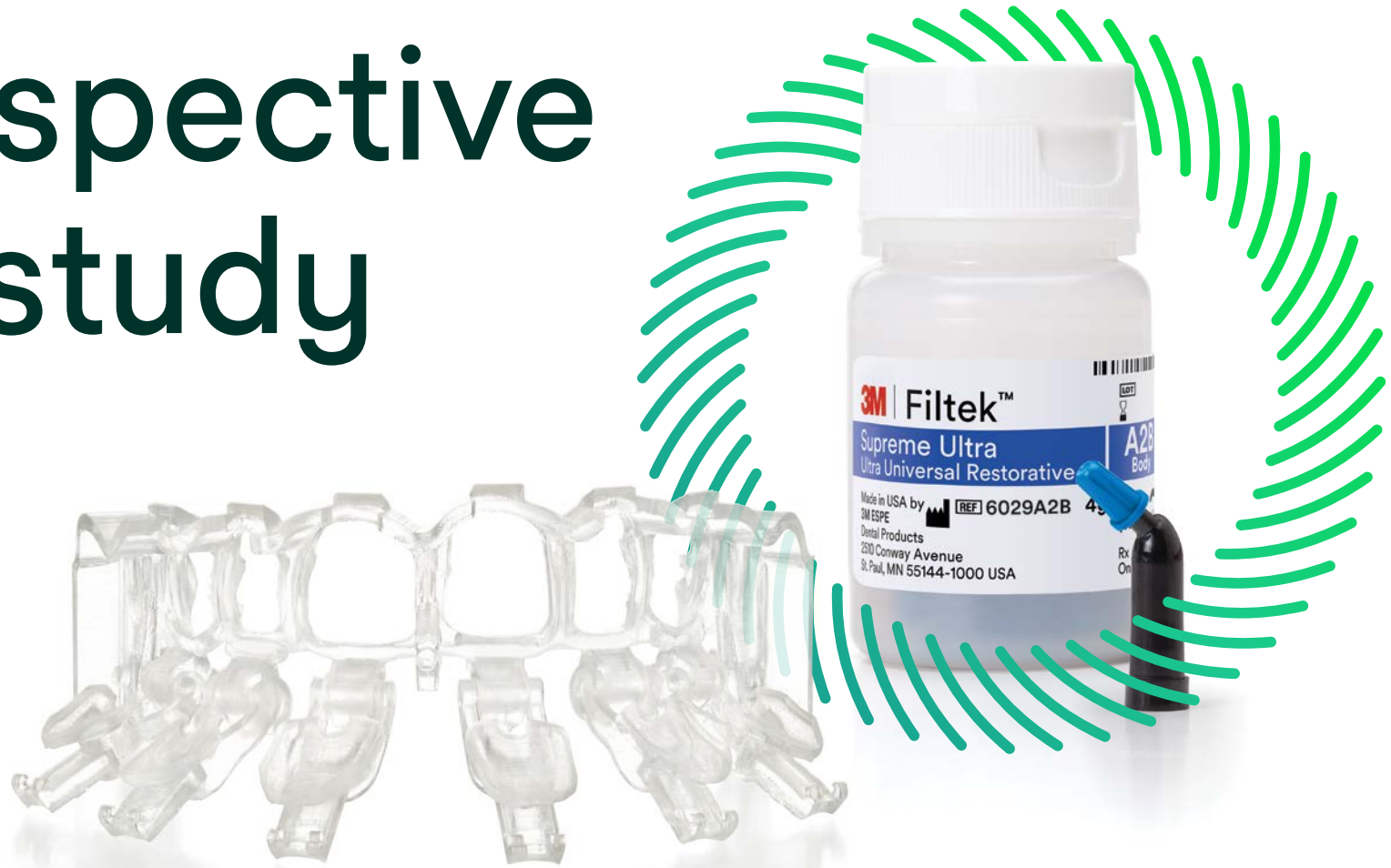



3M™ Filtek™ Matrix

Retrospective case study





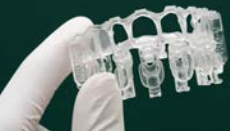
6-year follow-ups

Previous composite veneers and erosive enamel lost



Direct veneer with diastema closure

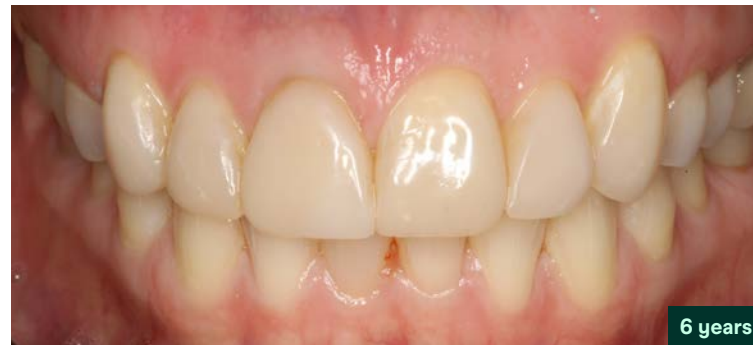
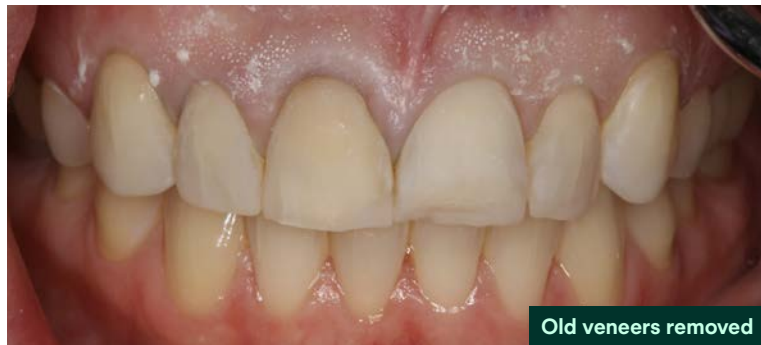
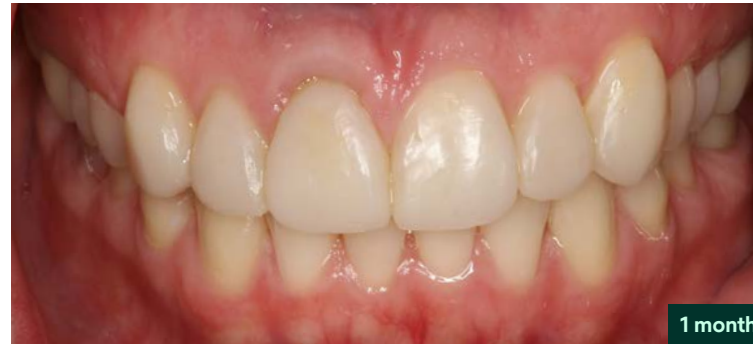
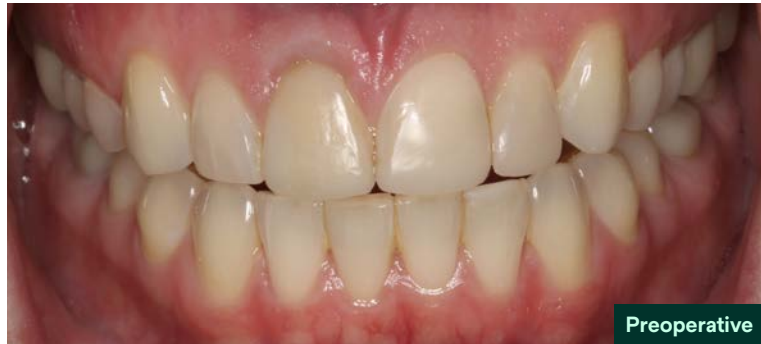
Previous composite veneers and erosive enamel lost (6 years post-op)

Teeth restored: #7-10

Clinical case courtesy of Dr. Adam Hodges



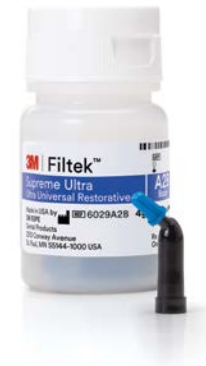About the case

- Patient desired replacement of previous composite veneers and enhancement of smile esthetics.
- Previous tooth fracture and erosive enamel loss decreased the smile esthetics of this mid 30's patient.
- Filtek Matrix allowed this conservative case to be done predictably in 1.5 hours in a busy restorative practice.

Clinical considerations

- In six plus years the only maintenance, other than routine prophylaxis, these restorations have required is repair of a chip caused by biting a fork.

Featured product:
3M™ Filtek™ Supreme Ultra Universal Restorative
Shade B1B

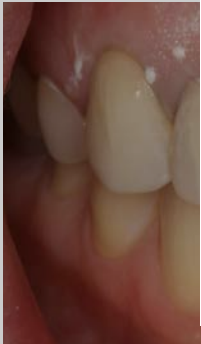
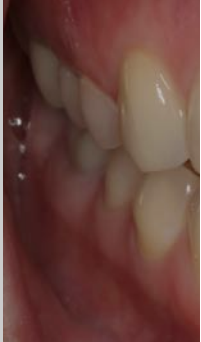


Previous composite veneers and erosive enamel lost (6 years post-op)

Teeth re

Clinical case cour



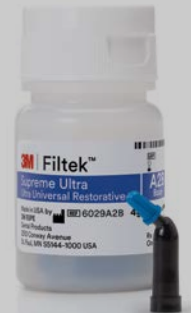Outcome

Previous composite veneers and erosive enamel lost (6 years post-op)

This patient felt that her smile did not match her age and desired esthetic improvement. Improved smile esthetics were accomplished with digital design and the Filtek Matrix to bring that design to life. At six plus years these restorations are going strong.

The patient was very pleased with the outcome as well as the limited chair time necessary to complete this case. At six years she is very satisfied with the results and is so happy her daughter has now had composite veneers completed using Filtek Matrix.

Featured product:
3M™ Filtek™ Supreme Ultra Universal Restorative
Shade B1B

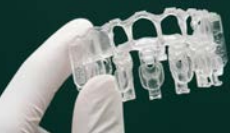

About the case

- Patient desired replacement of previous composite veneers and enhancement of smile esthetics.
- Previous tooth fracture and erosive enamel loss decreased the smile esthetics of this mid 30's patient.
- Filtek Matrix allowed this conservative case to be done predictably in 1.5 hours in a busy restorative practice.

Clinical considerations

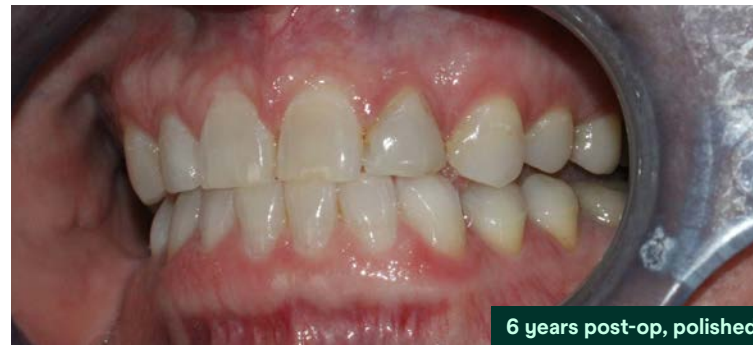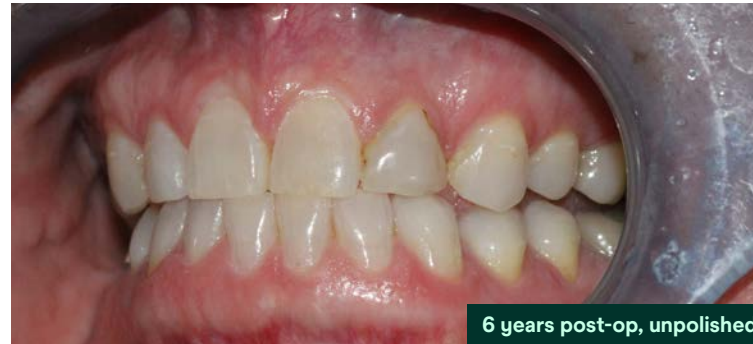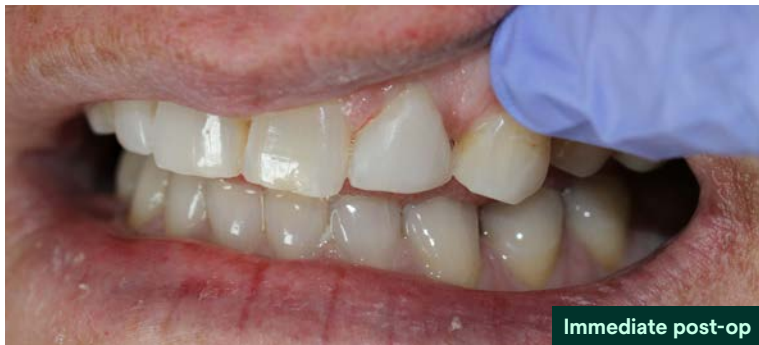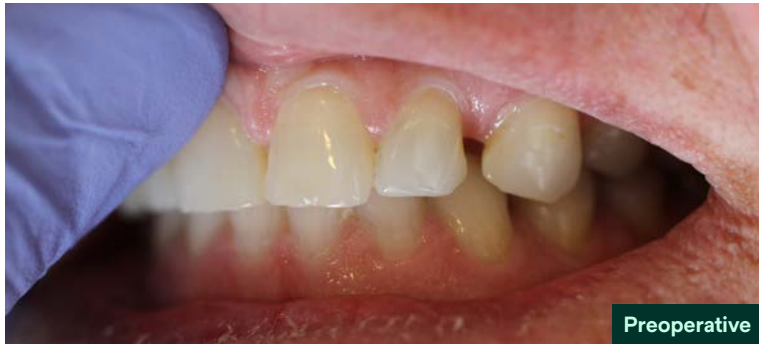- In six plus years the only maintenance, other than routine prophylaxis, these restorations have required is repair of a chip caused by biting a fork.



Direct veneer with diastema closure (6 years post-op)

Teeth restored: #10

Clinical case courtesy of Dr. Stephen Shaw



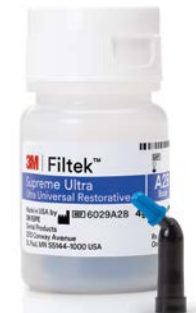About the case

- Patient presented with a considerable diastema distal to tooth #10.
- Freehand composite restorations placed many years prior had broken down severely over time (remnants evident in pre-op photo).
- Due to the longevity of the previous restorations, patient was motivated to use direct composites again. Her primary motivation was to simply look better in photos.

Clinical considerations

- The only tooth modification made prior to procedure was removal of existing composite from #10/11.
- Digital design confirmed that the diastema could adequately be closed with modification of #10 only and still yield acceptable proportion.

Featured product:
**3M™ Filtek™ Supreme Ultra
Universal Restorative**
Shade A1E

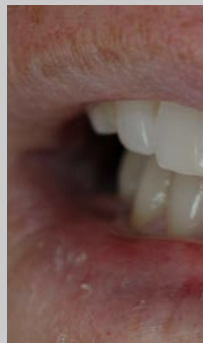




Direct veneer with diastema closure (6 years post-op)

Teeth re

Clinical case cour



About the

- Patient presented
- Freehand compo broken down sev
- Due to the longe motivated to use was to simply loc

Outcome

Direct veneer with diastema closure (6 years post-op)

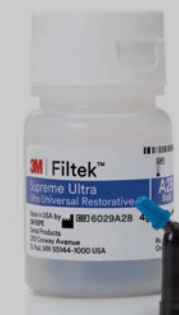This was the very first clinical case I performed with Filtek Matrix. I never like to use the terminology “quick and easy”, but that describes this case perfectly. The design was straight forward and the cosmetic demand was not complex.

The patient was very pleased with the immediate results due to her past experience with the prior procedure to fill the diastema. The clinical team was extremely impressed with the speed and accuracy of the entire process.

The patient is still very pleased with the result of the original procedure. The tooth has a slight gray hue to it due to a lingual amalgam that she did not want removed prior to original placement of the matrix procedure. She was inquiring about getting tooth #7 restored the same way when time permitted. After seeing this restoration for the first time in several years, I was pleased with the overall results, however I was reminded how important it is to polish the gingival margin thoroughly at time of placement (to avoid accumulation of stain).



Featured product:
3M™ Filtek™ Supreme Ultra Universal Restorative
Shade A1E





5-year follow-ups

Undersized teeth and diastemas



Composite veneers



Closing the gap




Previous trauma



Direct veneer with diastema closure



Post-orthodontic composite veneers

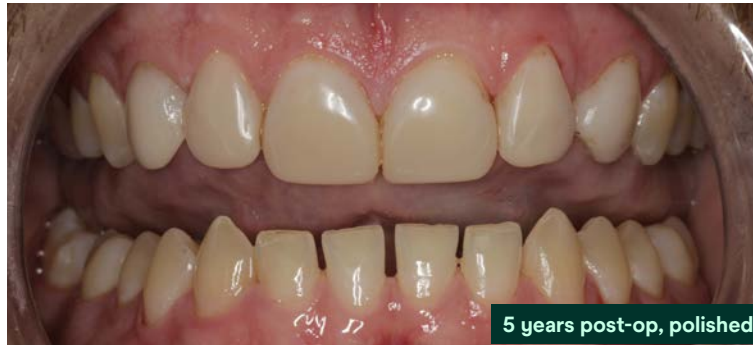
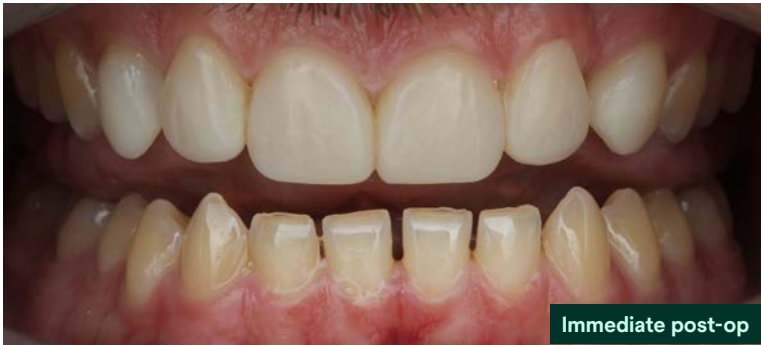
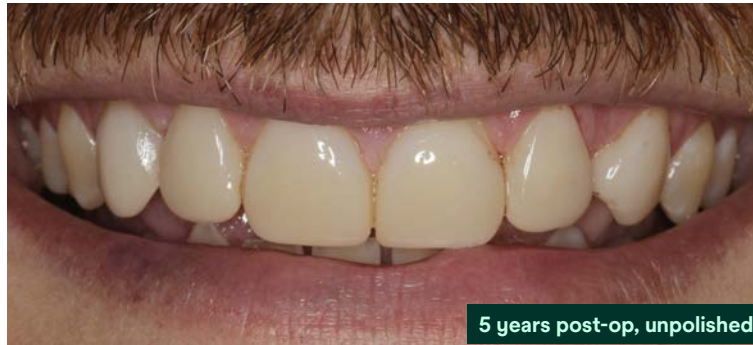
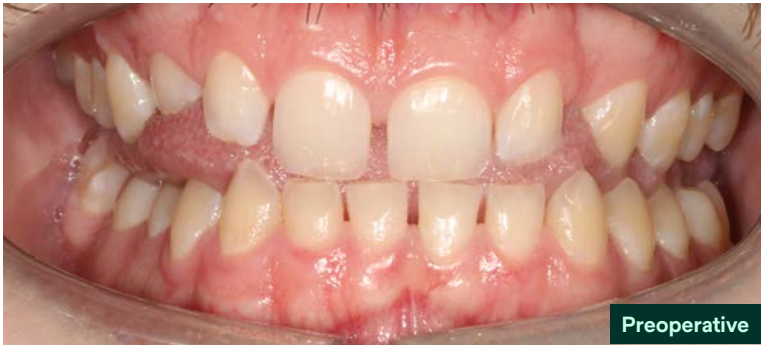
Undersized teeth and diastemas (5 years post-op)

Teeth restored: #6-11

Clinical case courtesy of Dr. Cappy Sinclair



About the case

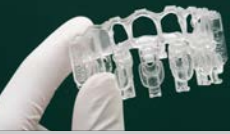- Diastemas and smaller teeth
- Patient was looking for an inexpensive way to address diastemas
- Financial constraints

Clinical considerations

- No reduction necessary
- Patient is on a six month hygiene interval, and limited concerns

Featured product:
**3M™ Filtek™ Supreme Ultra
Universal Restorative**
Shade B1B

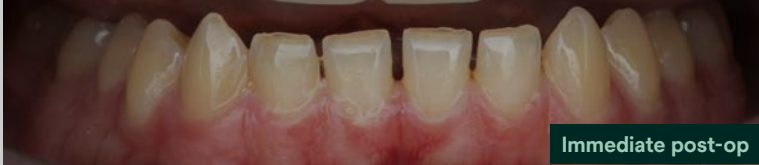
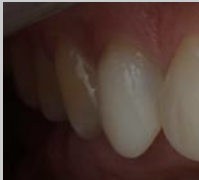
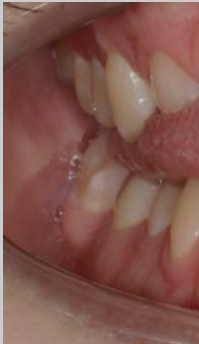

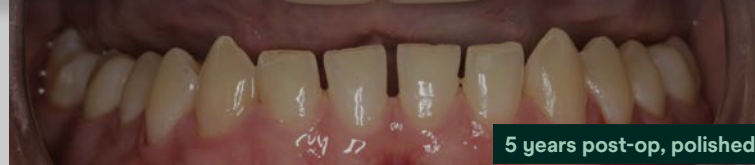Undersized teeth and diastemas (5 years post-op)

Teeth re

Clinical case cour



Immediate post-op



5 years post-op, polished

Outcome

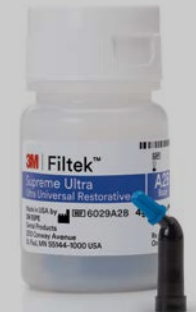Undersized teeth and diastemas

These restorations have held up very well over the years for the patient with one repair to the incisal edge of tooth #6 about six months ago.

The patient was thrilled with the immediate outcome and could not believe something like that was possible after living with his smile and teeth for so many years.



Featured product:
3M™ Filtek™ Supreme Ultra Universal Restorative
Shade B1B



About the case

- Diastemas and smaller teeth
- Patient was looking for an inexpensive way to address diastemas
- Financial constraints

Clinical considerations

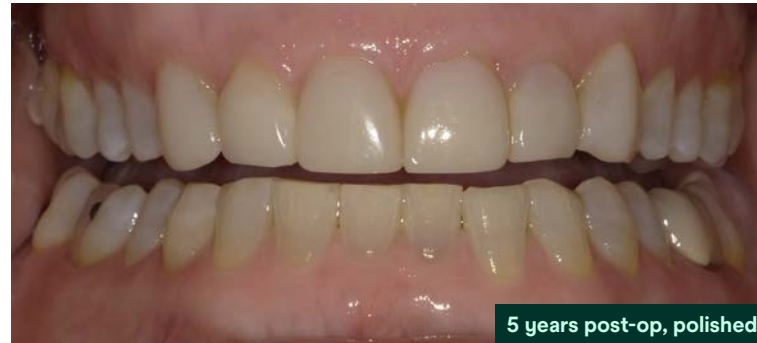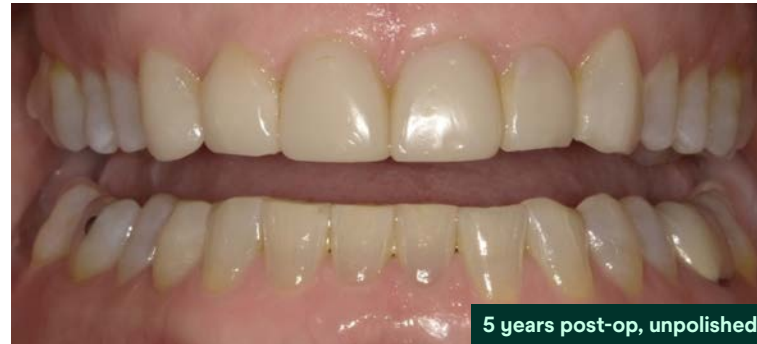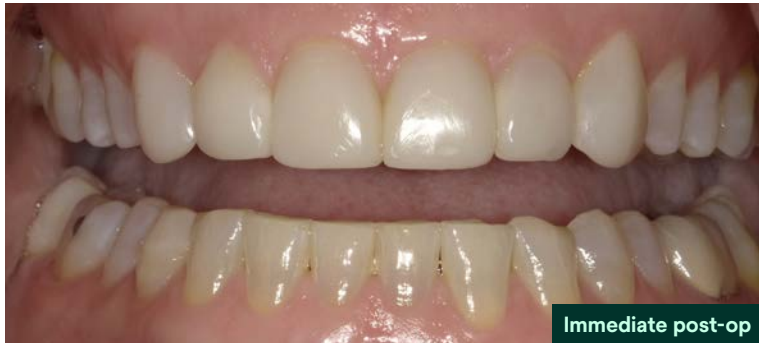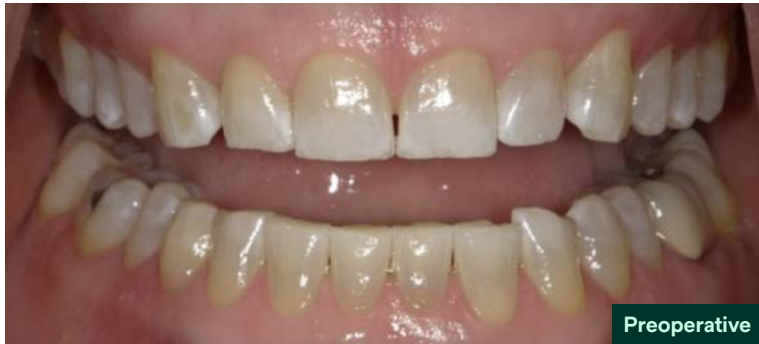- No reduction necessary
- Patient is on a six month hygiene interval, and limited concerns



Composite veneers (5 years post-op)

Teeth restored: #6-11

Clinical case courtesy of Dr. Lois Duerst



Featured product:
**3M™ Filtek™ Supreme Ultra
Universal Restorative**
Shade A1B



About the case

- Patient presented concerns about her smile including her flat incisal edges, some excess spaces distal to laterals and dark discoloration.
- Patient had short, worn anterior teeth giving her an older appearance. Her shade was A2 and she had excess space distal to the laterals, including a black triangle in the midline.
- Patient did not want her teeth cut down and wanted the most conservative treatment. Filtek Matrix and composite was her preferred restoration.

Clinical considerations

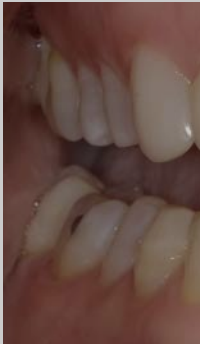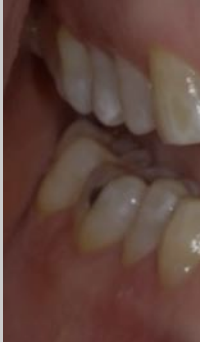- Patient whitened using at home trays and shade went from A2 to A1. We used Filtek Supreme Ultra Universal Restorative with the Filtek Matrix and restored teeth #6-11. The desired design added about 1mm to the length of each tooth and evenly closed the spaces between the laterals and canines.
- The patient has excellent hygiene habits and the result we see five years later reflects this. She is flossing and using an electric toothbrush. She avoids most stain causing foods and her color has maintained over the five years.



Composite veneers (5 years post-op)

Teeth re

Clinical case cour



About the

- Patient presented with uneven tooth edges, some extrusion, and a yellowish appearance. Her teeth were sensitive to the laterals, in particular.
- Patient did not want her teeth cut down and wanted the most conservative treatment. Filtek Matrix and composite was her preferred restoration.

Outcome

Composite veneers

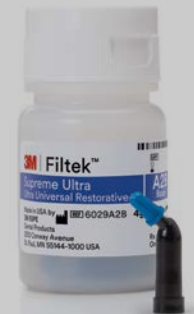This case is a great example of dentistry that looks past simply treating teeth but also focuses on treating a patient. This middle-aged male patient was suffering from multiple health issues which were all simultaneously degrading his anterior teeth. He exhibited signs of severe chemical erosion and displayed multiple failing restorations placed only a few years prior by another dentist. His autoimmune conditions make him a target for a multitude of recurrent host conditions such as, but not limited to, chronic gingivitis and lichen planus. The patient was desperate for restorative and cosmetic help. Due to health detriments as well as considerable financial constraints, the patient was extremely leery of having traditional indirect porcelain restorations placed.

Both the patient and the dental team were very pleased with the immediate **and** long-term outcomes of this treatment. Due to recurrent decay apical to the restorations, slight modifications have been needed over the years, at no fault to the restorations. Placing dental restorations will never be a cure for systemic conditions. Filtek Matrix gave this patient an outstanding restorative option which has weathered well in a very harsh environment for many years and confidently will continue for many more years to come.

- The patient has excellent hygiene habits and the result we see five years later reflects this. She is flossing and using an electric toothbrush. She avoids most stain causing foods and her color has maintained over the five years.



Featured product:
3M™ Filtek™ Supreme Ultra Universal Restorative
Shade A1B

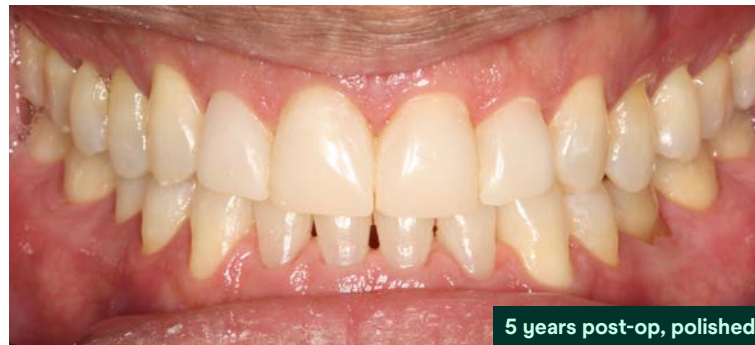
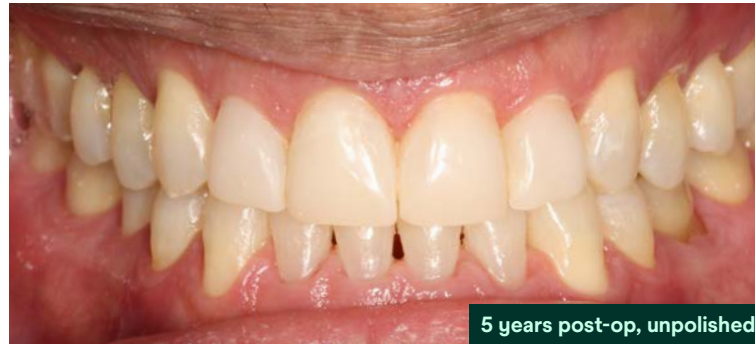
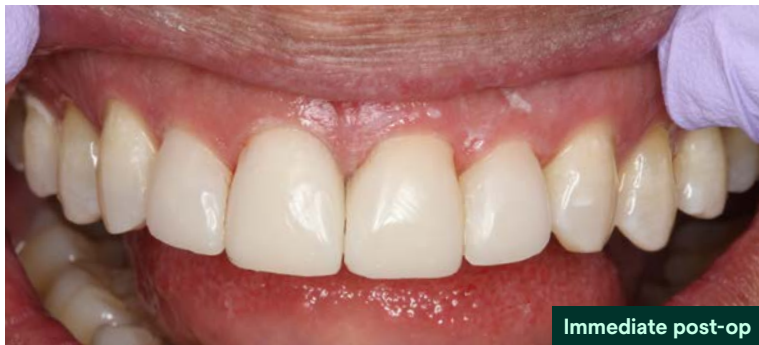
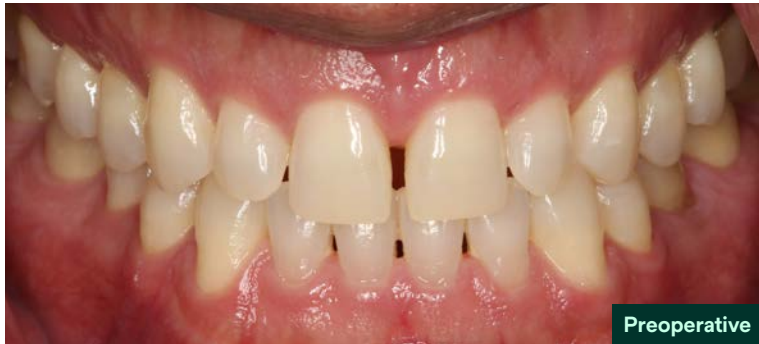
Closing the gap (5 years post-op)

Teeth restored: #7-10

Clinical case courtesy of Dr. Adam Hodges



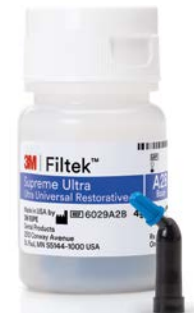About the case

- 42-year-old male
- Tooth shape/arch size discrepancy
- Filtek Matrix allows for additive restoration of the space without tooth reduction.

Clinical considerations

- The patient was self-conscious about the spacing around his teeth, but finance limited his ability to have porcelain veneers which is the only option he was offered.
- He is a very healthy patient. He has been seen regularly for prophylaxis and has required no follow up care for his treatment.

Featured product:
**3M™ Filtek™ Supreme Ultra
Universal Restorative**
Shade A1B

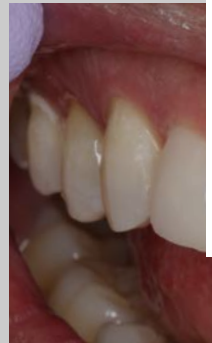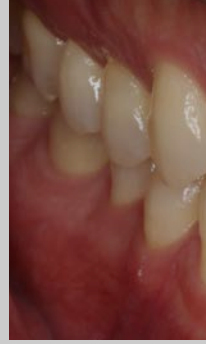




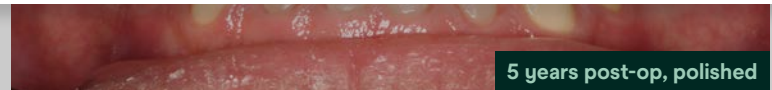Closing the gap (5 years post-op)

Teeth re

Clinical case cour



Immediate post-op



5 years post-op, polished

Outcome

Closing the gap

Filtek Matrix allowed this patient to have an approachable option to esthetically modify his teeth and reach the esthetic goals he desired. We distributed the shape change over the four maxillary incisors to keep proportions of the teeth more ideal.

He could not have been more pleased with the results and at five years. I am very happy with how things are holding up. This allows him to have an option to improve the esthetics of his smile without sacrificing his natural tooth structure.

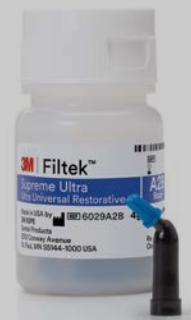About the case

- 42-year-old male
- Tooth shape/arch size discrepancy
- Filtek Matrix allows for additive restoration of the space without tooth reduction.

Clinical considerations

- The patient was self conscious about the spacing around his teeth, but finance limited his ability to have porcelain veneers which is the only option he was offered.
- He is a very healthy patient. He has been seen regularly for prophylaxis and has required no follow up care for his treatment.

Featured product:
3M™ Filtek™ Supreme Ultra Universal Restorative
Shade A1B

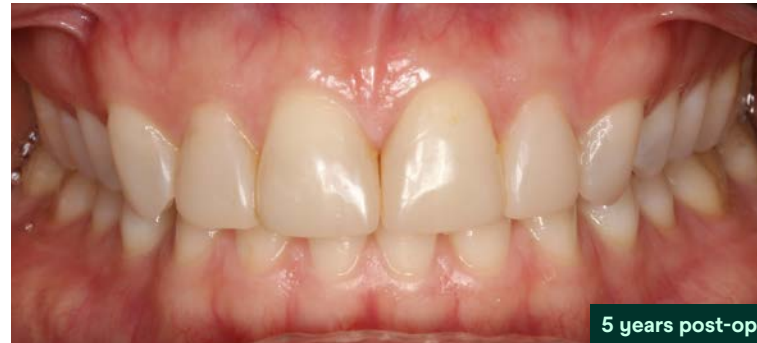
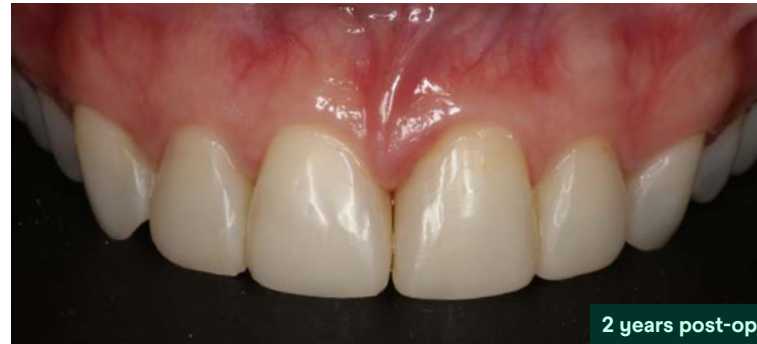
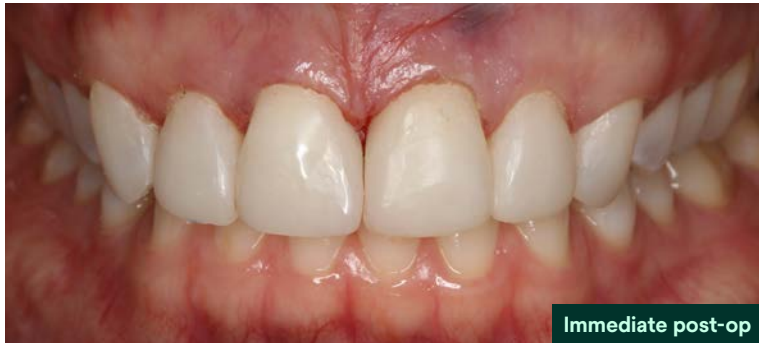
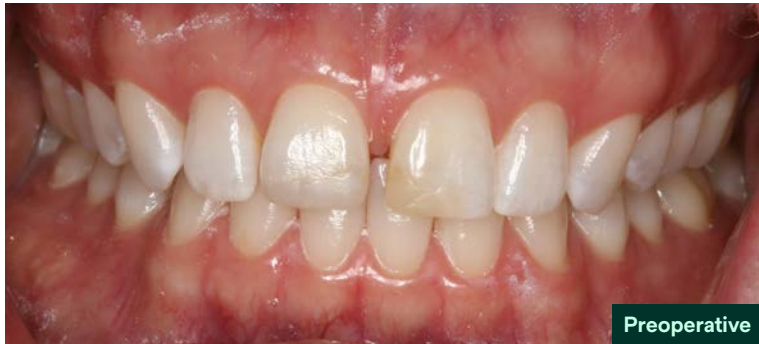
Previous trauma (5 years post-op)

Teeth restored: #7-10

Clinical case courtesy of Dr. Adam Hodges



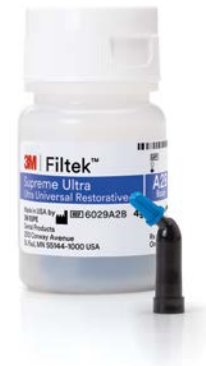About the case

- This patient had old composites from previous trauma as well as a diastema.
- She always desired cosmetic change to improve the diastema.
- Appositional addition to teeth and ease of treatment make this an ideal case for Filtek Matrix.

Clinical considerations

- She whitened her teeth which made the color of her previous composites stand out more. The size of the diastema dictated changing the incisors to distribute the space.
- We have seen her every six months for preventive maintenance, but her restorations have required no maintenance.

Featured product:
3M™ Filtek™ Supreme Ultra Universal Restorative
Shade A1B

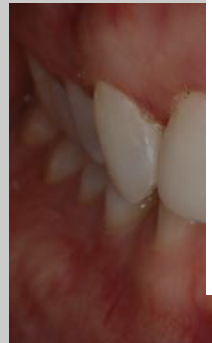
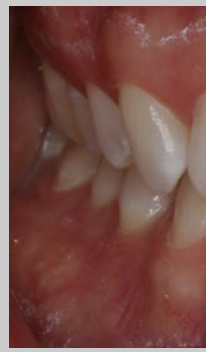


Previous trauma (5 years post-op)

Teeth re

Clinical case cour



Outcome

Previous trauma

In this case we used Filtek Matrix to distribute space among her maxillary incisions in an additive fashion. We did remove all existing composite to allow for color change as well as bonding directly to the tooth structure. The restorations have held up very well, and maintained a nice polish over their life.

She was very pleased and thankful for her transformation. She desired this change for quite some time and the Filtek Matrix allowed us to make this treatment approachable financially.

Immediate post-op

5 years post-op

About the case

- This patient had old composites from previous trauma as well as a diastema.
- She always desired cosmetic change to improve the diastema.
- Appositional addition to teeth and ease of treatment make this an ideal case for Filtek Matrix.

Clinical considerations

- She whitened her teeth which made the color of her previous composites stand out more. The size of the diastema dictated changing the incisors to distribute the space.
- We have seen her every six months for preventive maintenance, but her restorations have required no maintenance.

Featured product:
3M™ Filtek™ Supreme Ultra Universal Restorative
 Shade A1B

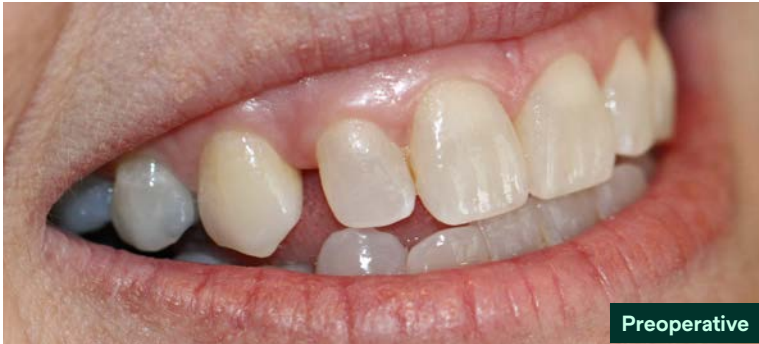



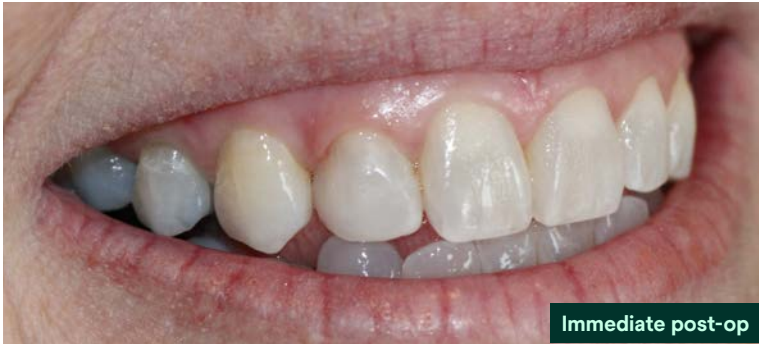Direct veneer with diastema closure (5 years post-op)

Teeth restored: #7

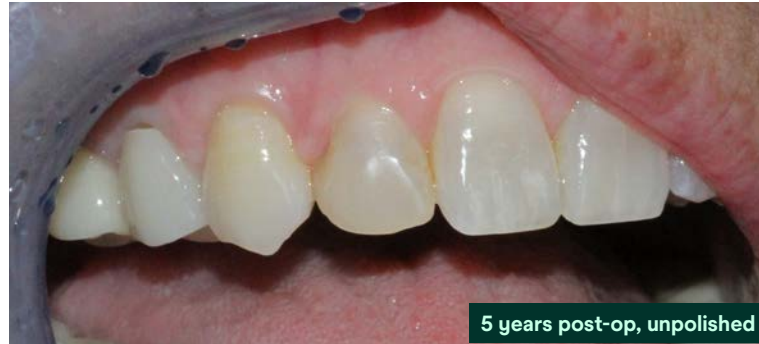Clinical case courtesy of Dr. Stephen Shaw



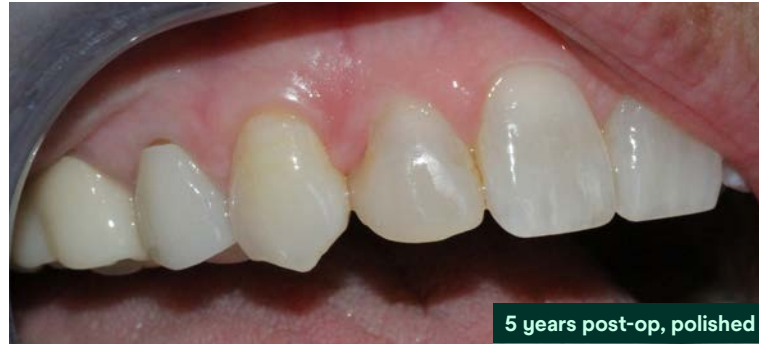Preoperative



Immediate post-op



5 years post-op, unpolished



5 years post-op, polished

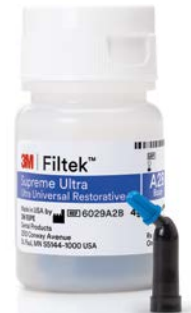About the case

- Patient presented with a considerable diastema distal to tooth #7.
- No previous restorations were placed on the tooth.
- Patient was motivated primarily by esthetics, and was not interested in porcelain laminate due to cost and tooth structure degradation.

Clinical considerations

- No tooth modification required—full facial coverage of tooth allowed for proper bulk and emergence profile.
- Start to finish was around 20 minutes.
- Digital design confirmed that the diastema could adequately be closed with good proportion by only restoring #7. Shade A2E used to blend with patient's existing shade.

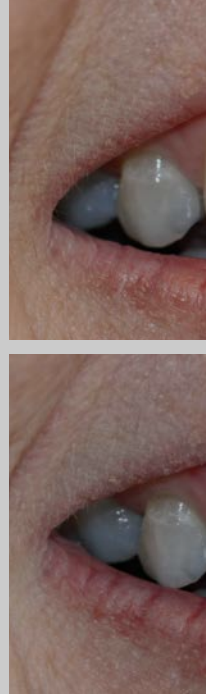
Featured product:
3M™ Filtek™ Supreme Ultra Universal Restorative
Shade A2E





Direct veneer with diastema closure (5 years post-op)

Teeth re
Clinical case cour



About the

- Patient presented with a diastema between teeth #6 and #7.
- No previous restorations were placed on the tooth.
- Patient was motivated primarily by esthetics, and was not interested in porcelain laminate due to cost and tooth structure degradation.

Outcome

Direct veneer with diastema closure

This case was a seemingly simple case but showed the capability of the Filtek Matrix to overcome a very challenging obstacle. When observing the pre-op image, you will notice that the gingival papilla in between #6/7 was very short and blunted. When restoring these cases with a mylar strip and a wedge apparatus, achieving a good emergence profile that preserves the papilla is downright difficult. Filtek Matrix made easy work of this, and actually improved the papilla shape to a more anatomic look!

The patient was very pleased with the immediate results of the procedure. She was able to achieve a more confident smile without spending a great deal of money and losing natural tooth structure.

The patient is still very pleased with the result of the original procedure. The restoration was observed to be very sound and should last for many years to come.

- Start to finish was around 20 minutes.
- Digital design confirmed that the diastema could adequately be closed with good proportion by only restoring #7. Shade A2E used to blend with patient's existing shade.



Featured product:
3M™ Filtek™ Supreme Ultra Universal Restorative
Shade A2E

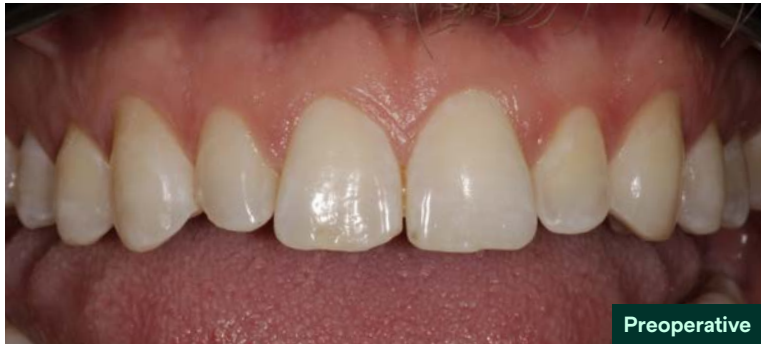



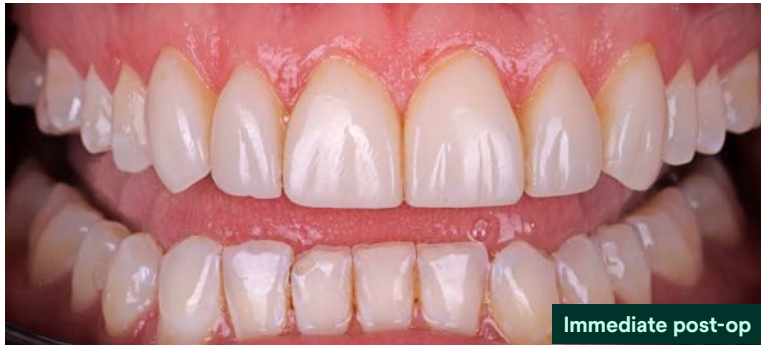Post-orthodontic composite veneers (5 years post-op)

Teeth restored: #6-11

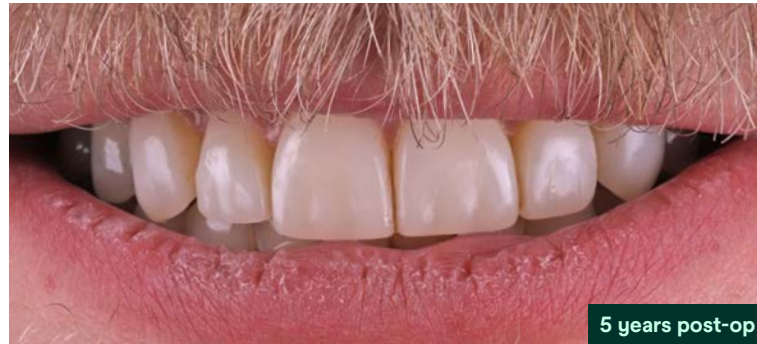Clinical case courtesy of Dr. Cappy Sinclair



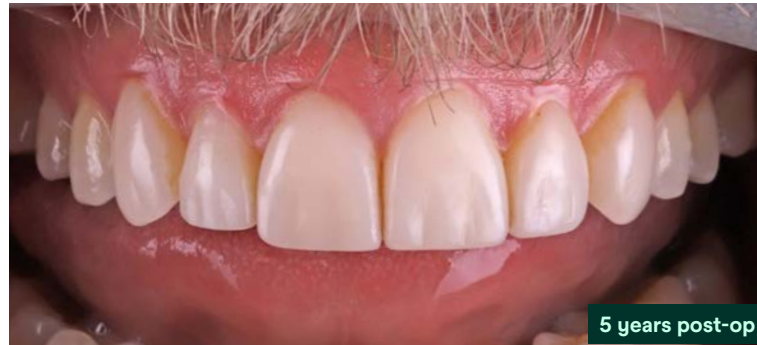Preoperative



Immediate post-op



5 years post-op



5 years post-op

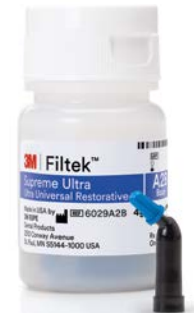About the case

- Undersized teeth
- Patient needed to have teeth sizes restored after orthodontic treatment
- Conservative option

Clinical considerations

- Whitening, orthodontic treatment
- Patient was also seen on a four month hygiene interval due to periodontal concerns, and also had stain build up due to tobacco use

Featured product:
3M™ Filtek™ Supreme Ultra Universal Restorative
Shade B1B

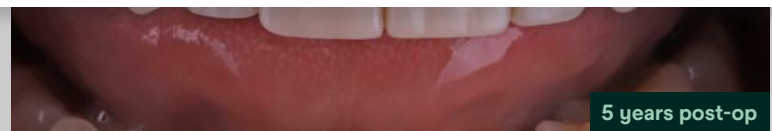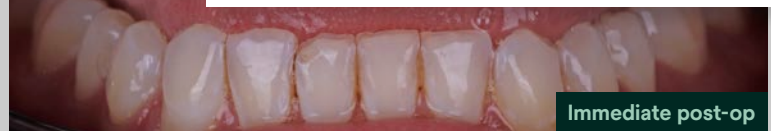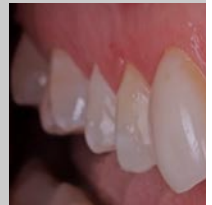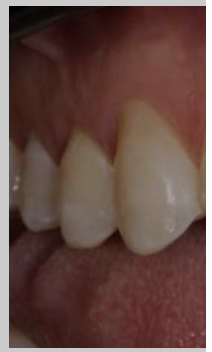




Post-orthodontic composite veneers (5 years post-op)

Teeth re

Clinical case cour



Outcome

Post-orthodontic composite veneers

The result has held up well given the patient's habits. I have noticed some color change relative to his lower teeth likely due to tobacco use and other habits. I have also had to repair the canine area once since the initial placement of the restorations.

The patient was very pleased with the outcome of the procedure immediately and with how they have held up over the years.



About the case

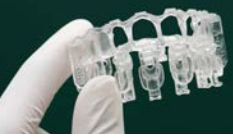- Undersized teeth
- Patient needed to have teeth sizes restored after orthodontic treatment
- Conservative option

Clinical considerations

- Whitening, orthodontic treatment
- Patient was also seen on a four month hygiene interval due to periodontal concerns, and also had stain build up due to tobacco use

Featured product:
**3M™ Filtek™ Supreme Ultra
 Ultra Universal Restorative**
 Shade B1B





4-year follow-ups

Tired of the gap




Composite veneers

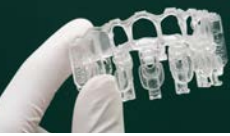

Old composite veneers replacement



Composite veneers

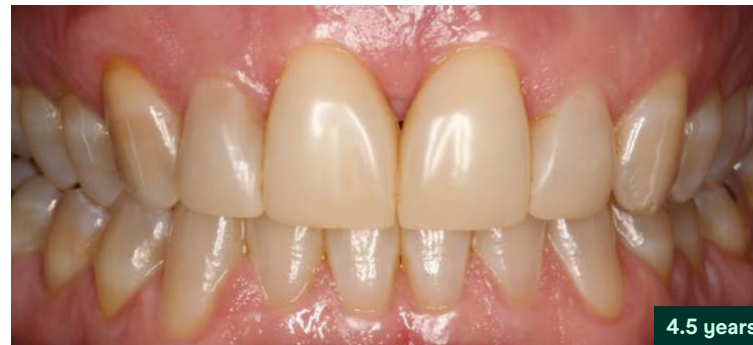
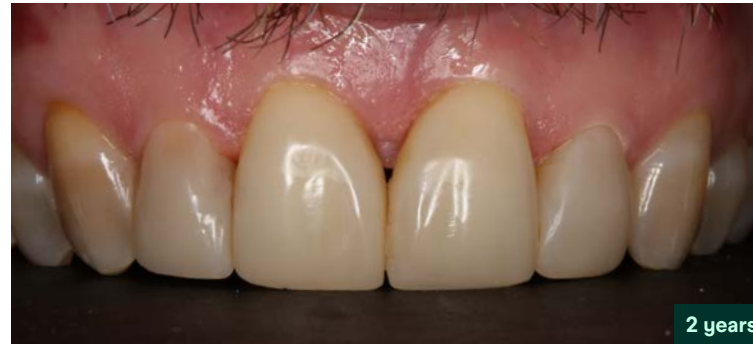
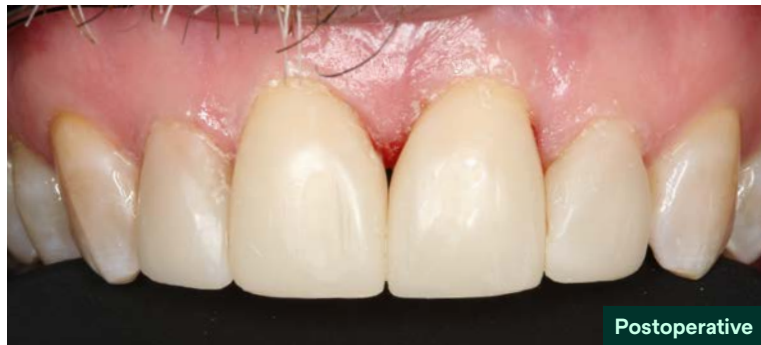
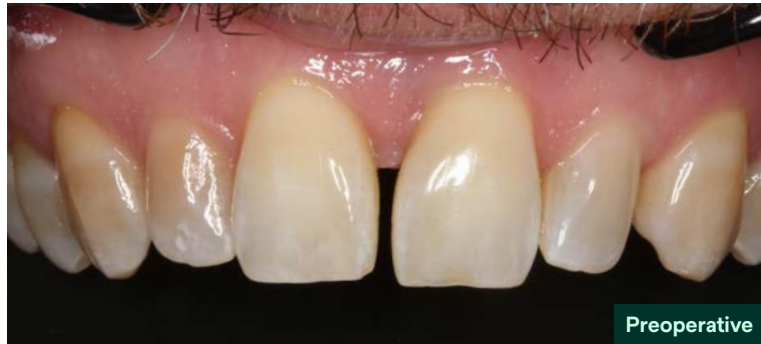
Tired of the gap (4.5 years post-op)

Teeth restored: #7-10

Clinical case courtesy of Dr. Adam Hodges



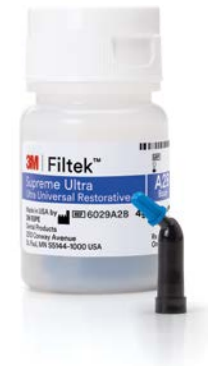About the case

- This patient had a long term desire to improve his smile esthetics
- Slightly undersized teeth coupled with a moderate diastema limited the esthetics of his smile
- Conservatism and reasonable cost were big factors in his desire to choose Filtek Matrix

Clinical considerations

- He previously tried whitening with some success. His main objective was minor color change and closing the diastema.
- He has been seen for regular prophylaxis and otherwise has required no maintenance on his treatment over the last four and a half years.

Featured product:
**3M™ Filtek™ Supreme Ultra
Universal Restorative**
Shade A2B

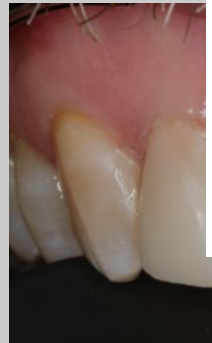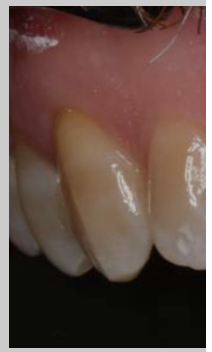




Tired of the gap (4.5 years post-op)

Teeth re

Clinical case cour



Postoperative

4.5 years

Outcome

Tired of the gap

Filtek Matrix makes cases like this one very simple. After digital design, the matrix allows for very efficient restoration of these teeth. They have held up very well and have required no additional maintenance.

Over the last 4.5 years I have seen this patient every six months. He is very happy with his treatment and is good about maintaining his hygiene which is always beneficial for longevity of the restorations.

About the case

- This patient had a long term desire to improve his smile esthetics
- Slightly undersized teeth coupled with a moderate diastema limited the esthetics of his smile
- Conservatism and reasonable cost were big factors in his desire to choose Filtek Matrix

Clinical considerations

- He previously tried whitening with some success. His main objective was minor color change and closing the diastema.
- He has been seen for regular prophylaxis and otherwise has required no maintenance on his treatment over the last four and a half years.

Featured product:
3M™ Filtek™ Supreme Ultra Universal Restorative
 Shade A2B

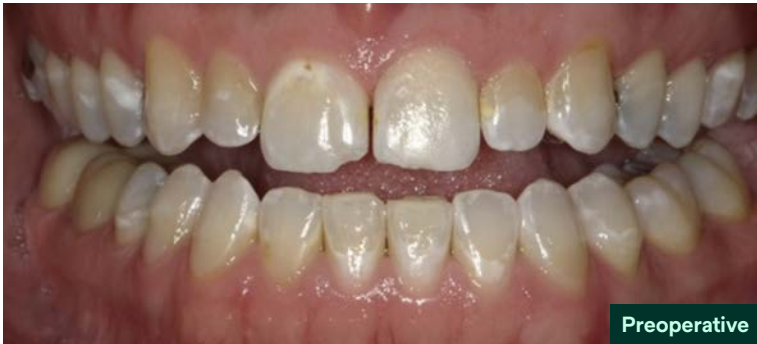



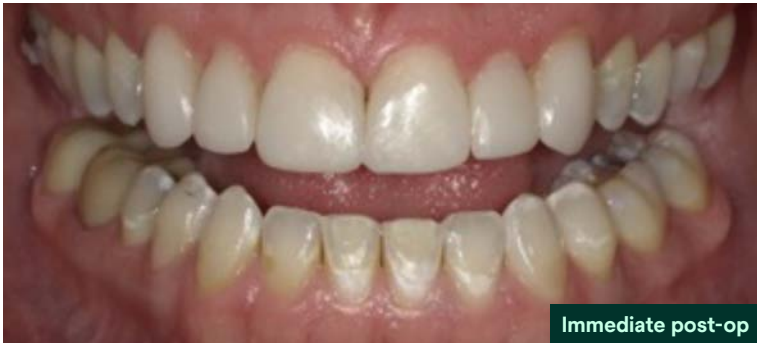Composite veneers (4 years post-op)

Teeth restored: #6-11

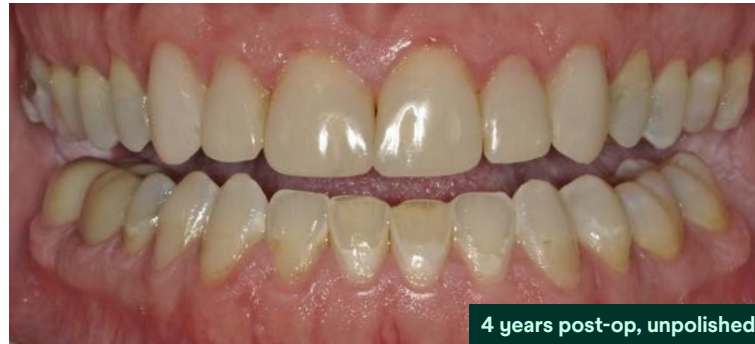Clinical case courtesy of Dr. Lois Duerst



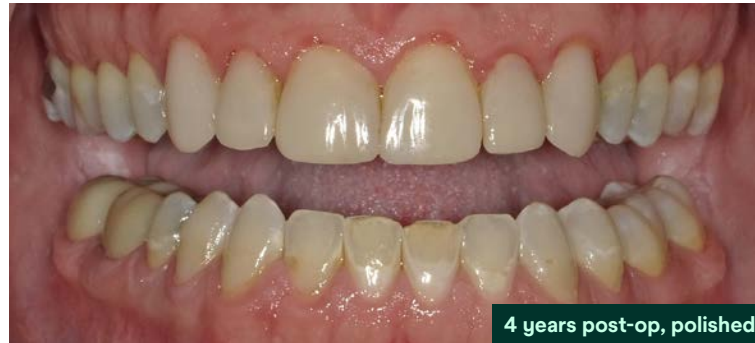Preoperative



Immediate post-op



4 years post-op, unpolished



4 years post-op, polished

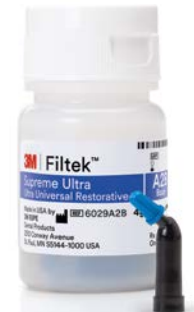About the case

- Patient presented stating that he didn't like his smile. He felt his teeth were discolored and he didn't like the white spots.
- The patient had white spot lesions from having braces as a child. Some of those had progressed to carious lesions. He also had a chip on his front tooth as well as a midline diastema.
- Patient wanted a nicer smile but didn't want the expense of porcelain veneers. Using the Filtek Matrix and composite was a perfect solution.

Clinical considerations

- The patient required several fillings prior to placing the veneers as well as treating the white spot lesions. He did at home whitening and had excellent results, going from A4 to B1. We closed the spaces and lengthened the four anterior teeth to match the canines.
- The patient has taken great care of his restorations using an electric toothbrush and flossing. The shade has diminished a bit in brightness as he drinks three to four cups of coffee per day.

Featured product:
**3M™ Filtek™ Supreme Ultra
Universal Restorative**
Shade B1B

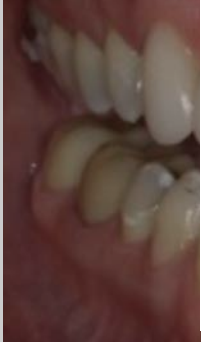
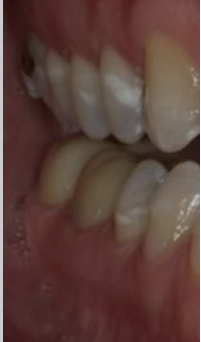


Composite veneers (4 years post-op)

Teeth re

Clinical case cour



Outcome

Composite veneers

I was pleasantly surprised at how the shine and gloss has remained over four years. I did polish up the composites a bit, especially along the gingival margins, but that process is quick and easy. The patient has not experienced any issues with chipping or wearing of the composites.

The patient was in his twenties when we did the restorations four years ago, so he was thrilled at how much younger and better his smile looked. He had been embarrassed to smile and now smiles without hesitation. He still loves the results and states that the teeth feel very natural.



Featured product:
3M™ Filtek™ Supreme Ultra Universal Restorative
Shade B1B



About the case

- Patient presented stating that he didn't like his smile. He felt his teeth were discolored and he didn't like the white spots.
- The patient had white spot lesions from having braces as a child. Some of those had progressed to carious lesions. He also had a chip on his front tooth as well as a midline diastema.
- Patient wanted a nicer smile but didn't want the expense of porcelain veneers. Using the Filtek Matrix and composite was a perfect solution.

Clinical considerations

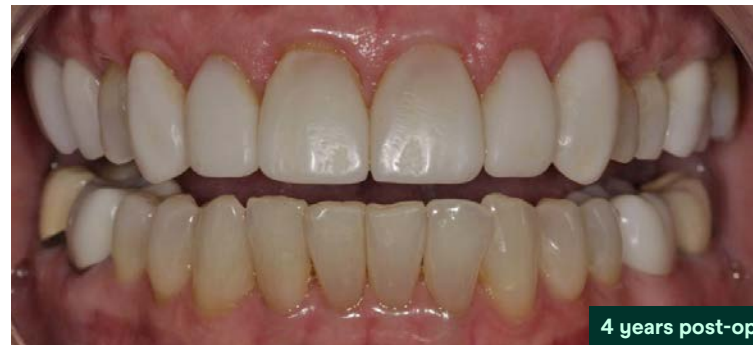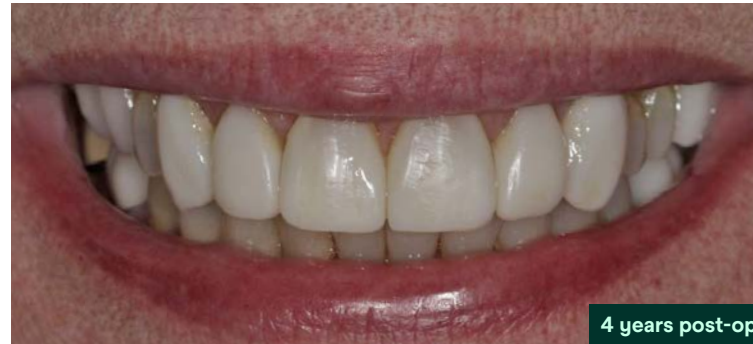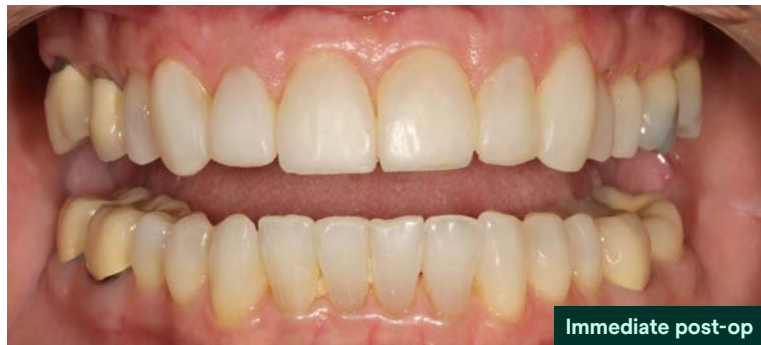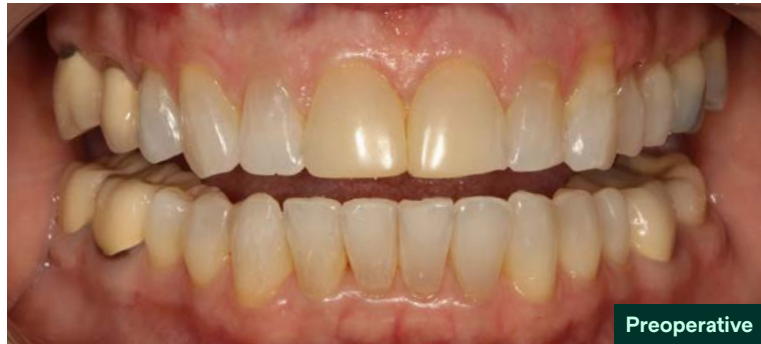- The patient required several fillings prior to placing the veneers as well as treating the white spot lesions. He did at home whitening and had excellent results, going from A4 to B1. We closed the spaces and lengthened the four anterior teeth to match the canines.
- The patient has taken great care of his restorations using an electric toothbrush and flossing. The shade has diminished a bit in brightness as he drinks three to four cups of coffee per day.



Old composite veneers replacement (4 years post-op)

Teeth restored: #6-11

Clinical case courtesy of Dr. Cappy Sinclair



About the case

- Patient was looking for a brighter smile and replacement of the current bonding on teeth 8 and 9
- The patient had darker teeth with concerns of her previous bonding
- The patient chose composite over porcelain due to the investment

Clinical considerations

- Whitening was used first, reduction was also used to help block out the darker tooth shades.
- Patient has had several health concerns over the last few years and has increased medications that create xerostomia concerns. She is on a three months hygiene interval due to decay risks.

Featured product:
**3M™ Filtek™ Supreme Ultra
Ultra Universal Restorative**
Shade WB

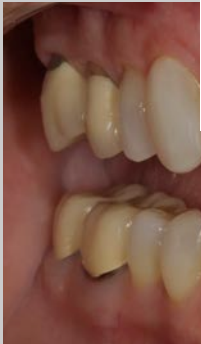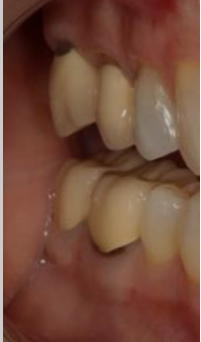




Old composite veneers replacement (4 years post-op)

Teeth re

Clinical case cour

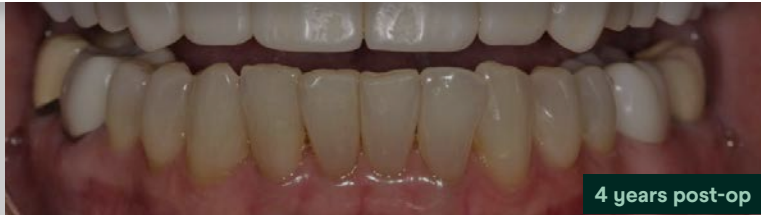

X

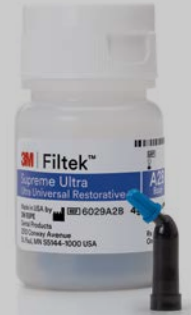Outcome

Old composite veneers replacement

The Restorations have held up well given the patients health concerns. No repairs or replacements have been made. There has been a decrease in value over time with the composite, likely due to the health concerns and medications. The patient was very happy with the final result.



Featured product:
**3M™ Filtek™ Supreme Ultra
Ultra Universal
Restorative**
Shade WB



About the case

- Patient was looking for a brighter smile and replacement of the current bonding on teeth 8 and 9
- The patient had darker teeth with concerns of her previous bonding
- The patient chose composite over porcelain due to the investment

Clinical considerations

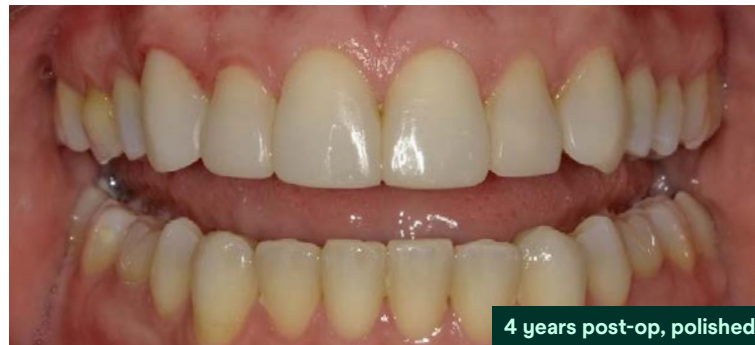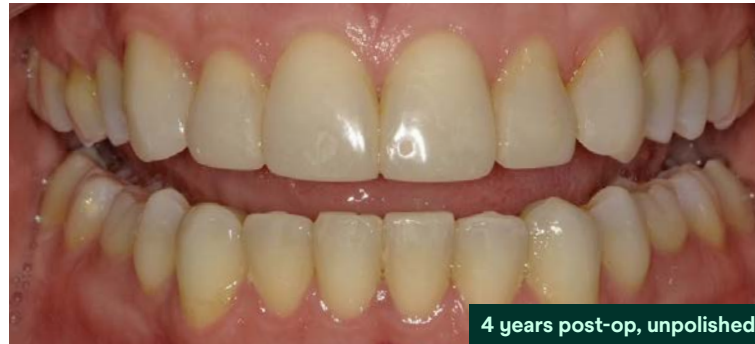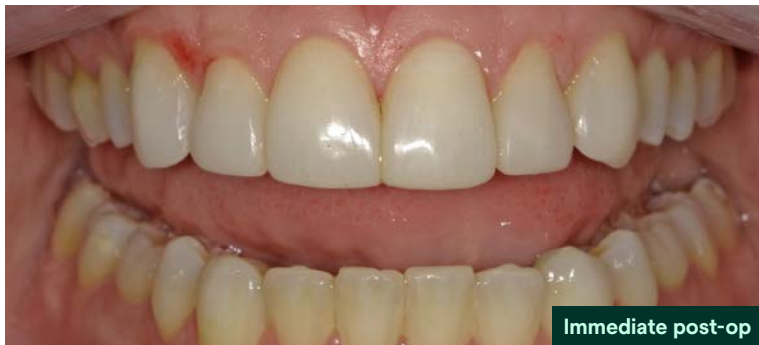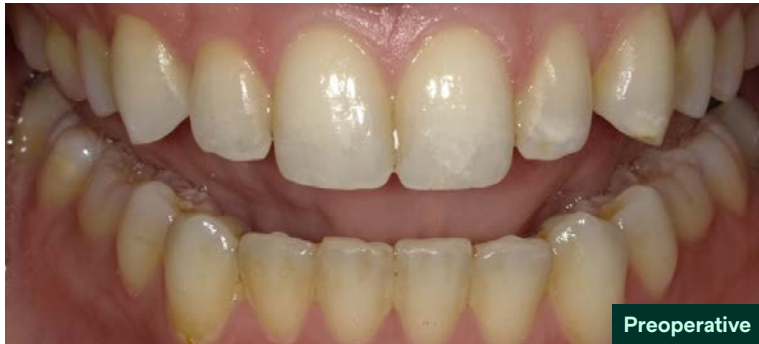- Whitening was used first, reduction was also used to help block out the darker tooth shades.
- Patient has had several health concerns over the last few years and has increased medications that create xerostomia concerns. She is on a three months hygiene interval due to decay risks.



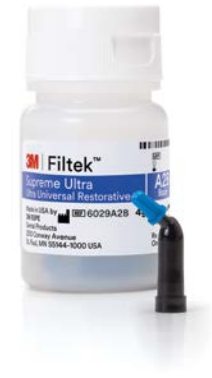Composite veneers (4 years post-op)

Teeth restored: #6-11

Clinical case courtesy of Dr. Lois Duerst



Featured product:
**3M™ Filtek™ Supreme Ultra
Universal Restorative**
Shade A1B



About the case

- Patient presented with a complaint that her front teeth were too long and skinny compared to her other teeth. She also did not like the white spots.
- The patient had some hypoplastic lesions on several of her anterior teeth. She also had spaces to the distal of the laterals and long centrals.
- The patient absolutely did not want her teeth cut down and preferred composite veneers over porcelain.

Clinical considerations

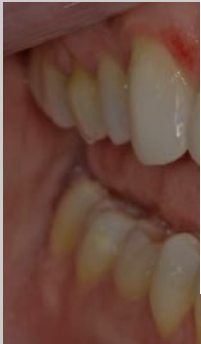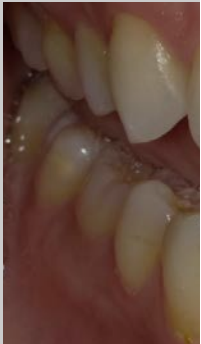- The patient did at home whitening and the shade went from A2 to W. As part of the design, we shortened her central incisors and added 1mm to the laterals and canines to give a more proportional smile.
- The patient has a bit of dry mouth so she, in general, gets a lot of plaque buildup. She does use an electric toothbrush and flosses. We reviewed brushing technique to keep the gingiva healthy. Tooth #11 has a small chip on the incisal edge that corresponded to her guidance. It was not rough, and we left as is.



Composite veneers (4 years post-op)

Teeth re

Clinical case cour



Immediate post-op

4 years post-op, polished

Outcome

Composite veneers

The teeth were still shiny and polished after four years. The patient had some gingival irritation due to her dry mouth, but the veneers felt smooth, and the margins closed. No staining was noted but a small chip was present on #11, corresponding to her guidance. In general, the case looked spectacular after four years.

The patient was very happy when we originally did the case as her teeth looked more proportional and even. She continues to be pleased with the results and expressed how happy she was that she did the restorations.



Featured product:
**3M™ Filtek™ Supreme Ultra
Universal Restorative**
Shade A1B



About the case

- Patient presented with a complaint that her front teeth were too long and skinny compared to her other teeth. She also did not like the white spots.
- The patient had some hypoplastic lesions on several of her anterior teeth. She also had spaces to the distal of the laterals and long centrals.
- The patient absolutely did not want her teeth cut down and preferred composite veneers over porcelain.

Clinical considerations

- The patient did at home whitening and the shade went from A2 to W. As part of the design, we shortened her central incisors and added 1mm to the laterals and canines to give a more proportional smile.
- The patient has a bit of dry mouth so she, in general, gets a lot of plaque buildup. She does use an electric toothbrush and flosses. We reviewed brushing technique to keep the gingiva healthy. Tooth #11 has a small chip on the incisal edge that corresponded to her guidance. It was not rough, and we left as is.



3-year follow-ups

Peg laterals immediate orthodontic post-op




Composite veneers



Orthodontic spacing and discoloration



Post-orthodontic composite veneers

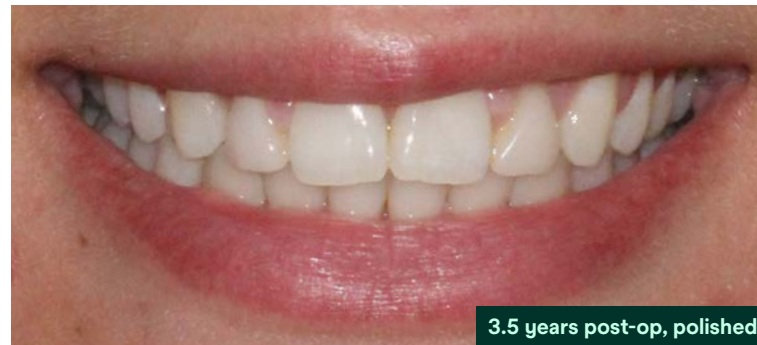
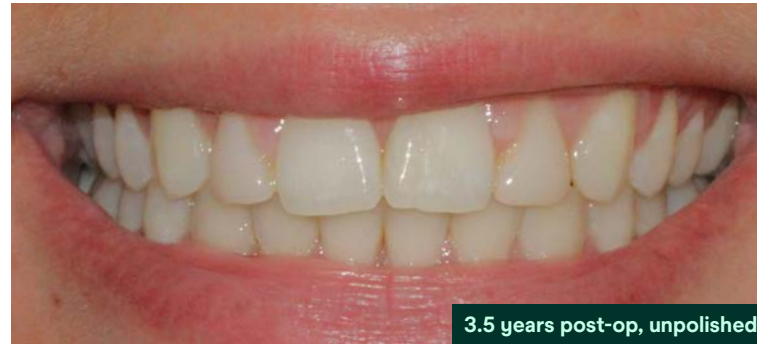
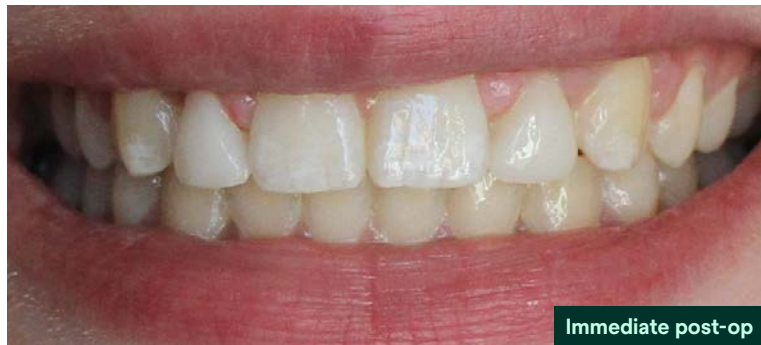
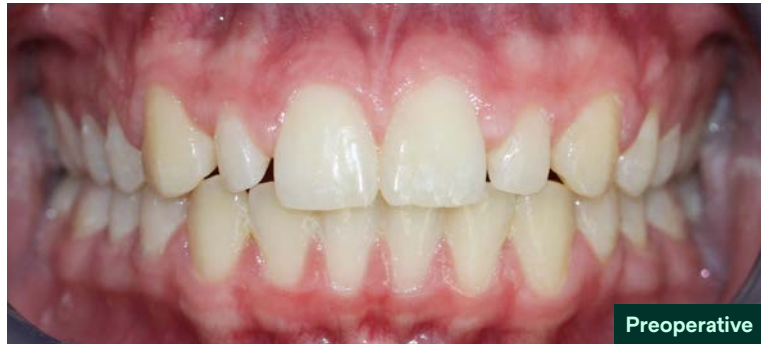
Peg laterals immediate orthodontic post-op (3.5 years post-op)

Teeth restored: #7, #10

Clinical case courtesy of Dr. Stephen Shaw



Featured product:
**3M™ Filtek™ Supreme Ultra
Universal Restorative**
Shade B1B



About the case

- Cosmetic bonding immediately following orthodontic treatment
- Teenage patient with no health/dental complications
- Patient wanted immediate results that were as noninvasive as possible and economical due to a grandparent paying for the treatment

Clinical considerations

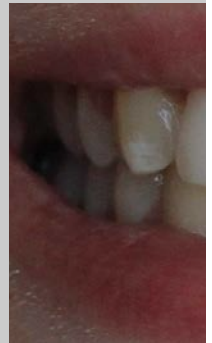
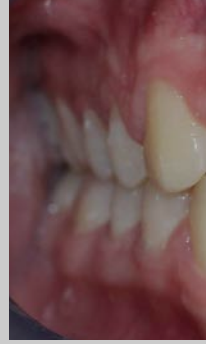
- Patient came straight from orthodontist office after debanding. There was no whitening or reduction performed on #7 or #10
- Patient is a nonsmoker with no known deleterious habits that might affect the longevity of the restorations



Peg laterals immediate orthodontic post-op (3.5 years post-op)

Teeth re

Clinical case cour



About the

- Cosmetic bondir
- Teenage patient
- Patient wanted immediate results that were as noninvasive as possible and economical due to a grandparent paying for the treatment

Outcome

Peg laterals immediate orthodontic post-op

This was a really fun, quick, enjoyable case. One of the best parts about the case was the fact that she came to start the procedure with a fair amount of anxiety due to the debanding process at the orthodontist being very uncomfortable for her.

After fit confirmation, the process was over in less than 20 minutes, and she was ecstatic! At no point was the procedure uncomfortable or anxiety inducing. She was thrilled with the way the new restorations looked and felt.

As the practitioner, I was thrilled due to the speed and effectiveness of the procedure. In the days of conventional approaches to this type of restoration, the process could easily be much longer in duration and still not achieve the desired results.

As observed, the restorations have held up very well and the patient is still very much enamored with her lateral incisors. In fact, she is in training to become a dental assistant.

... affect the longevity of the restorations



Featured product:
3M™ Filtek™ Supreme Ultra Universal Restorative
Shade B1B

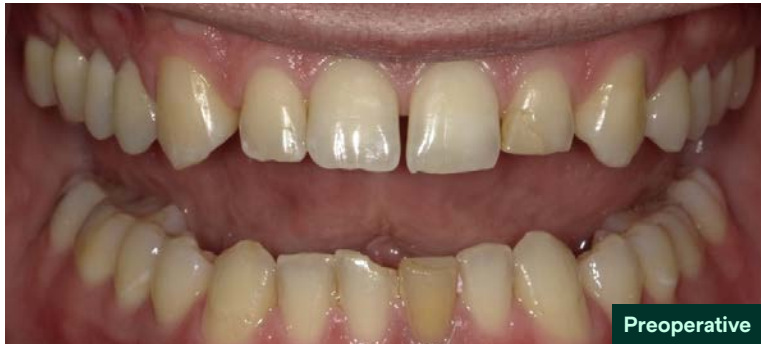



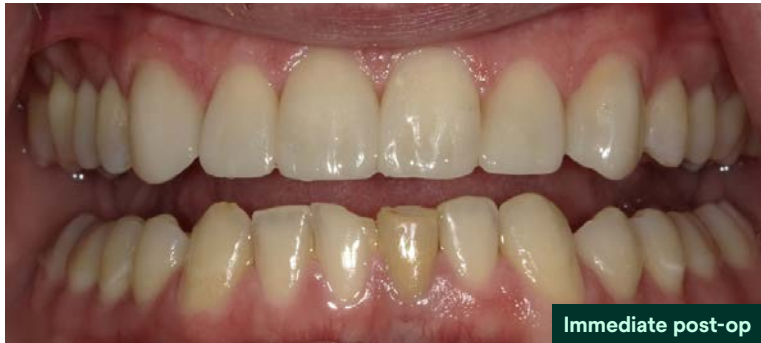Composite veneers (3 years post-op)

Teeth restored: #6-11

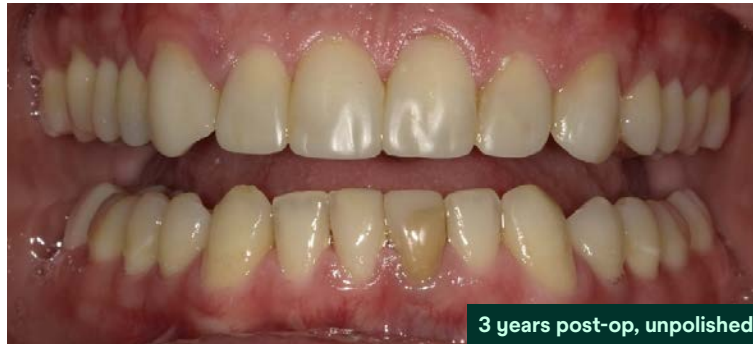Clinical case courtesy of Dr. Lois Duerst



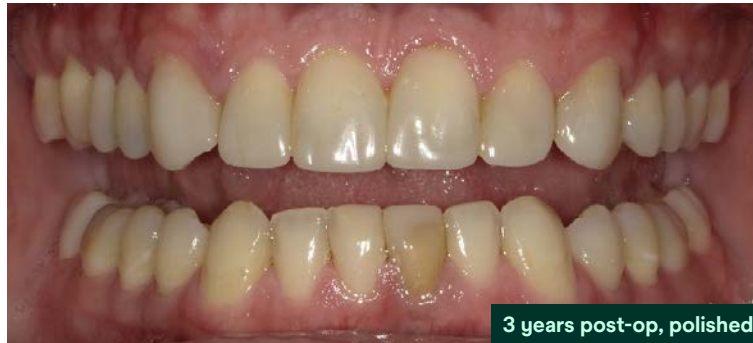Preoperative



Immediate post-op



3 years post-op, unpolished



3 years post-op, polished

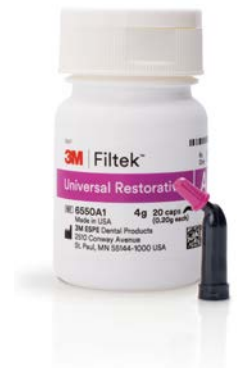About the case

- Patient presented unhappy with the esthetics of his smile
- Multiple diastemas were present in his MX anterior teeth. He had a reverse smile in that his front 4 teeth were short in comparison to his canines. Tooth #10 also had a discolored filling as well as being a different width than #7.
- Patient was not interested in the cost or the more aggressive prep of porcelain veneers. This was a perfect additive case where composite could be used.

Clinical considerations

- Teeth #7-10 were lengthened to correlate to #6 and #11 and all spaces closed evenly
- Patient has great oral hygiene which is shown in the health of his gingiva and the continued success of his composite veneers. Patient does drink coffee but, in general, takes great care to keep his new smile looking great.

Featured product:
3M™ Filtek™ Universal Restorative
Shade A1

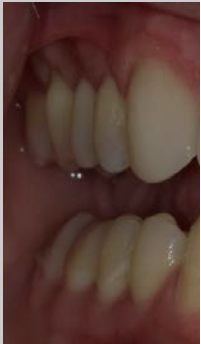
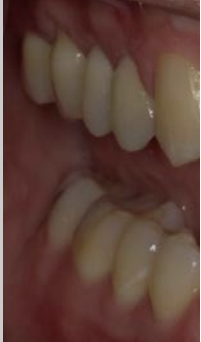


Composite veneers (3 years post-op)

Teeth re

Clinical case cour



Outcome

Composite veneers

The composite shade and polish have remained consistent and ideal over the three years of this case. The patient did return after about one and one-half years with a chip on #11 which was related to an occlusal interference. The occlusal issue was resolved, and the composite repaired quickly and easily. I anticipate these veneers will last long into the future.

The patient was thrilled to see the difference in his smile when the restorations were completed three years ago, especially the impact of lengthening his front four teeth. He continues to be happy with his smile and has found it to feel natural and comfortable. He has no regrets on the treatment and looks forward to many years of use.

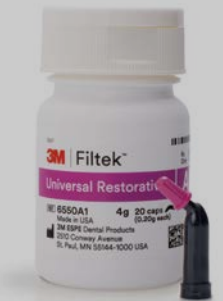About the case

- Patient presented unhappy with the esthetics of his smile
- Multiple diastemas were present in his MX anterior teeth. He had a reverse smile in that his front 4 teeth were short in comparison to his canines. Tooth #10 also had a discolored filling as well as being a different width than #7.
- Patient was not interested in the cost or the more aggressive prep of porcelain veneers. This was a perfect additive case where composite could be used.

Clinical considerations

- Teeth #7-10 were lengthened to correlate to #6 and #11 and all spaces closed evenly
- Patient has great oral hygiene which is shown in the health of his gingiva and the continued success of his composite veneers. Patient does drink coffee but, in general, takes great care to keep his new smile looking great.

Featured product:
3M™ Filtek™ Universal Restorative
Shade A1

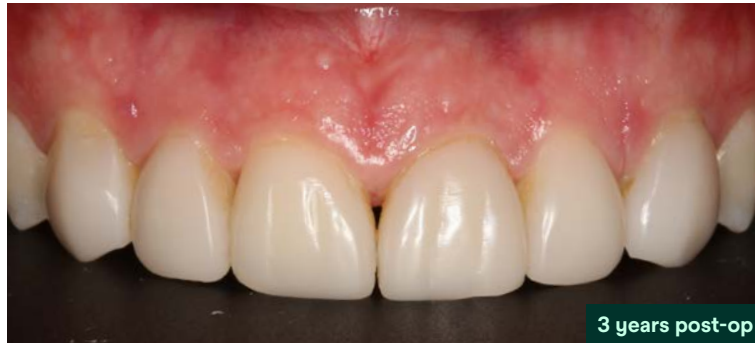
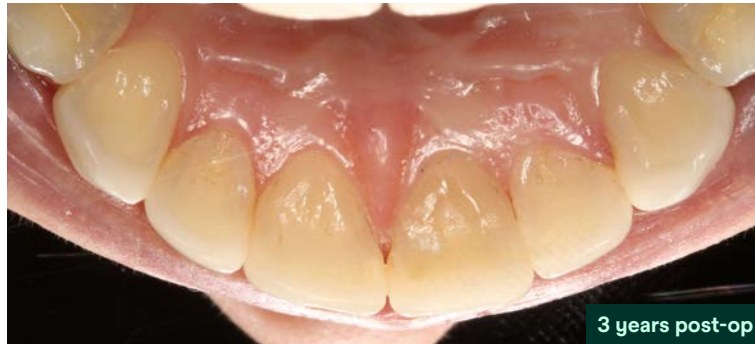
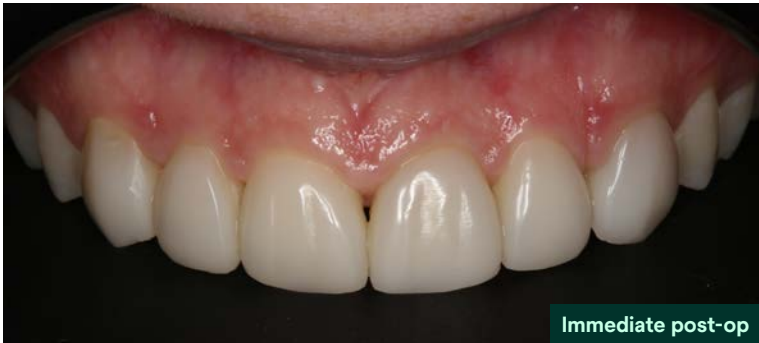
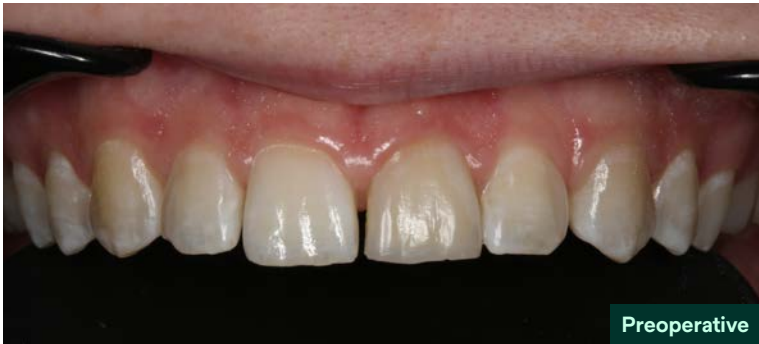
Orthodontic spacing and discoloration (3 years post-op)

Teeth restored: #6-11

Clinical case courtesy of Dr. Adam Hodges



About the case

- Post-orthodontic spacing and dark endodontically treated tooth #9 created patient motivation for esthetic change.
- This teenager had a Bolton discrepancy which created diastema between her anterior teeth even with previous bonding.
- Filtek Matrix is ideal for this young patient to allow for conservative restoration without tooth reduction preserving her natural tooth integrity.

Clinical considerations

- Six teeth were treated without tooth reduction using Filtek Supreme Ultra Universal Restorative shade B1B. Body shaded composite allowed for length and width addition without excessive translucency.
- At three years, the composite is holding up very well with no more than routine prophylaxis as maintenance.

Featured product:
3M™ Filtek™ Supreme Ultra Universal Restorative
Shade B1B

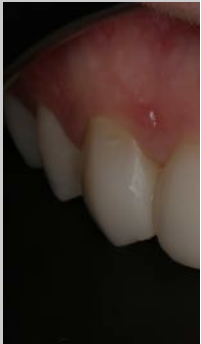
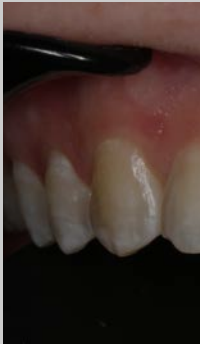


Orthodontic spacing and discoloration (3 years post-op)

Teeth re

Clinical case cour



About the

- Post-orthodontic spacing created patient n
- This teenager had a Bolton discrepancy which created diastema between her anterior teeth even with previous bonding.
- Filtek Matrix is ideal for this young patient to allow for conservative restoration without tooth reduction preserving her natural tooth integrity.

Outcome

Orthodontic spacing and discoloration

When teeth cannot be orthodontically positioned without spacing, it creates an esthetic challenge for the restorative dentist. For any patient, tooth structure preservation is always a high priority, not only for longevity, but structural integrity. Composite resin allows us to check the boxes by providing long lasting esthetic restorations while preserving tooth structure, and becomes a win for patient and dentist. A lot of dentists have anxiety about providing this treatment. This is why the Filtek Matrix is a great tool for a restorative dentist. It allows for predictable treatment in a predictable amount of time to fit in our busy schedule.

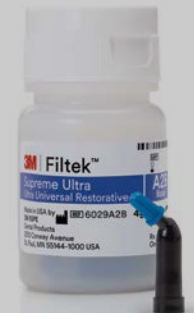This teenager and her parents could not be happier. We were able to provide the esthetic change they desired and provide a shade improvement to provide a beautiful smile. This solution allows for conservative restoration of the teeth and predictable results for the dentist.

composite allowed for length and width addition without excessive translucency.

- At three years, the composite is holding up very well with no more than routine prophylaxis as maintenance.



Featured product:
3M™ Filtek™ Supreme Ultra Universal Restorative
Shade B1B

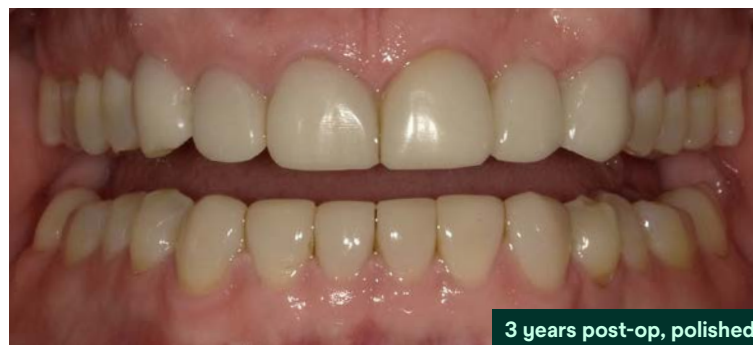
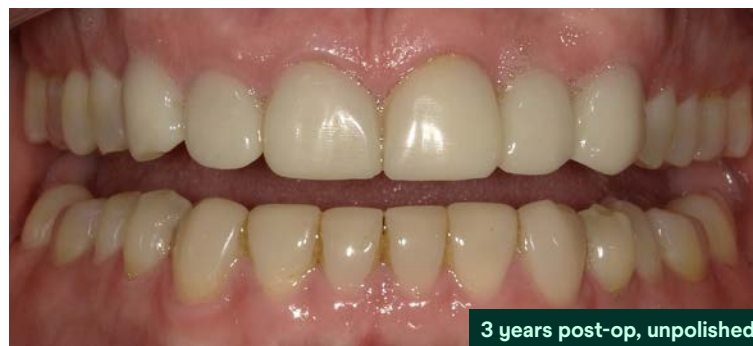
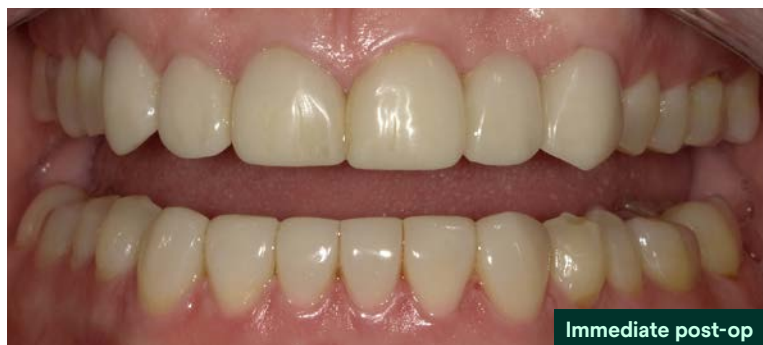
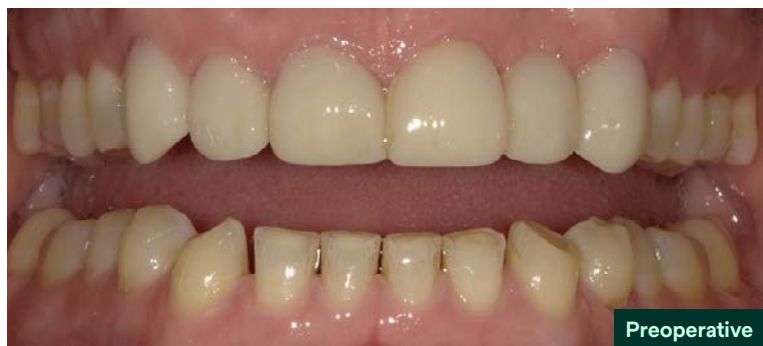
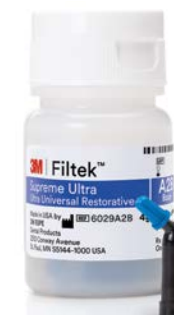Post-orthodontic composite veneers (3 years post-op)

Teeth restored: #22-27

Clinical case courtesy of Dr. Lois Duerst



Featured product:
**3M™ Filtek™ Supreme Ultra
Universal Restorative**
Shade A2B



About the case

- Patient presented worry about wear on his lower teeth and unhappy with the esthetics of his older, MX anterior crowns and bridges.
- Patient had 25-year-old MX porcelain crowns/bridge that had worn the lower anterior dentition. Lower incisors erupted over time and the cycle continued. Treatment involved the coordination of an orthodontist to intrude his lower teeth, restorative dentist to replace upper fixed restorations and me to restore his lower teeth properly.
- Due to the case complexity, timing and cost, patient really wanted his lower teeth restored with composite veneers.

Clinical considerations

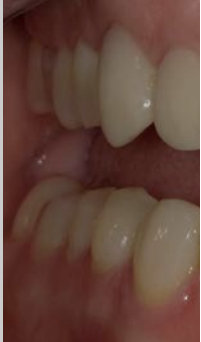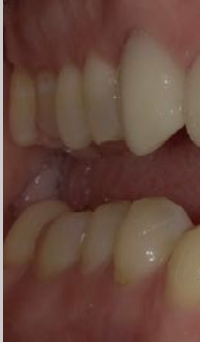- Patient had orthodontics for about two years to put his teeth back where they belonged. His upper crowns and bridge were replaced with a long term temporary while we completed his lower teeth using the Filtek Matrix.
- Patient has been wearing a retainer/night guard every night and plans to wear into the future to protect his new restorations. After three years, he had a bit of marginal stain due to his two to three cup coffee habit, but that was easily polished with strips. The gum tissue looks fantastic due to the patient's ideal oral hygiene habits.



Post-orthodontic composite veneers (3 years post-op)

Teeth re

Clinical case cour



About the

- Patient presented worry about wear on his lower teeth and unhappy with the esthetics of his older, MX anterior crowns and bridges.
- Patient had 25-year-old MX porcelain crowns/bridge that had worn the lower anterior dentition. Lower incisors erupted over time and the cycle continued. Treatment involved the coordination of an orthodontist to intrude his lower teeth, restorative dentist to replace upper fixed restorations and me to restore his lower teeth properly.
- Due to the case complexity, timing and cost, patient really wanted his lower teeth restored with composite veneers.

Outcome

Post-orthodontic composite veneers

This is probably one of the nicest cases I have done, both esthetically and from a patient satisfaction viewpoint. It has been really gratifying collaborating with other professionals to create a plan and work together to the finished product. While the polish has remained excellent over the three years, I anticipate that I will need to polish any coffee stain off every few years. Patient is more than happy having that done and it takes a few minutes to do. Overall, I am very pleased with the ease and continued success of this case.

The patient had short, worn lower anterior teeth for so long that he was amazed and so happy when those teeth were restored back to normal shape and height. He feels confident that his bite and esthetics will remain healthy and will last a long time with the continued use of a lower nightguard and continued good habits and care.

- Patient had orthodontics for about two years to put his teeth back where they belonged. His upper crowns and bridge were replaced with a long term temporary while we completed his lower teeth using the Filtek Matrix.
- Patient has been wearing a retainer/night guard every night and plans to wear into the future to protect his new restorations. After three years, he had a bit of marginal stain due to his two to three cup coffee habit, but that was easily polished with strips. The gum tissue looks fantastic due to the patient's ideal oral hygiene habits.




Featured product:
3M™ Filtek™ Supreme Ultra Universal Restorative
Shade A2B





2-year follow-up

Post-orthodontic
tooth lengthening

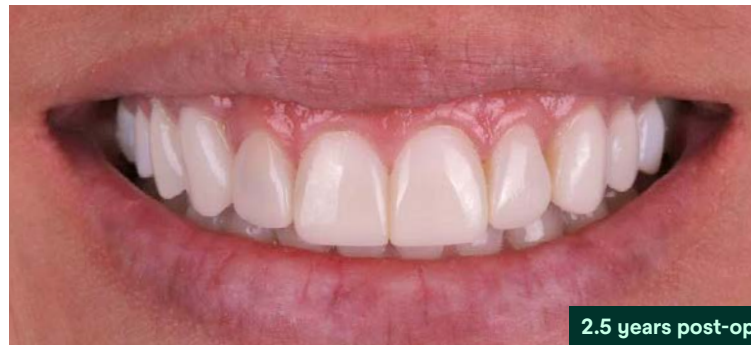
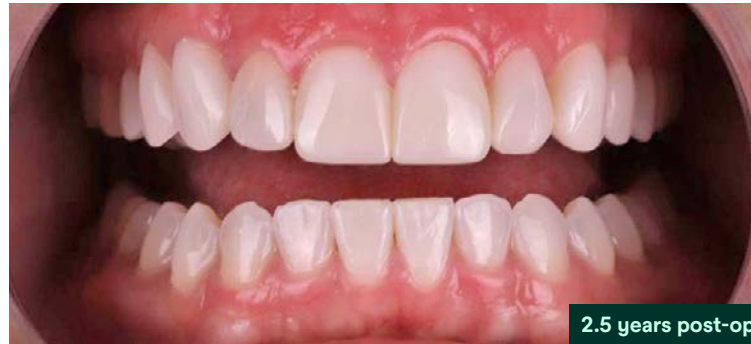
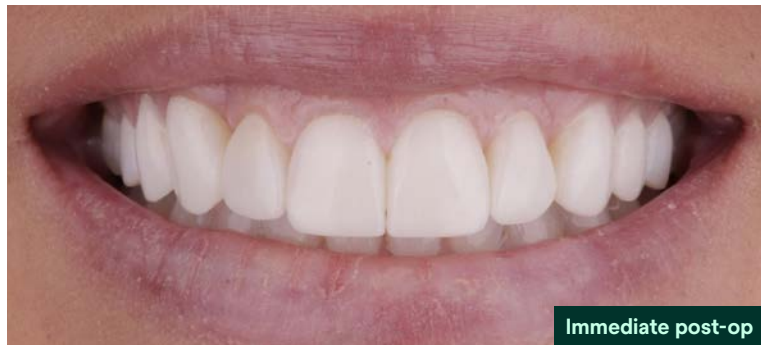
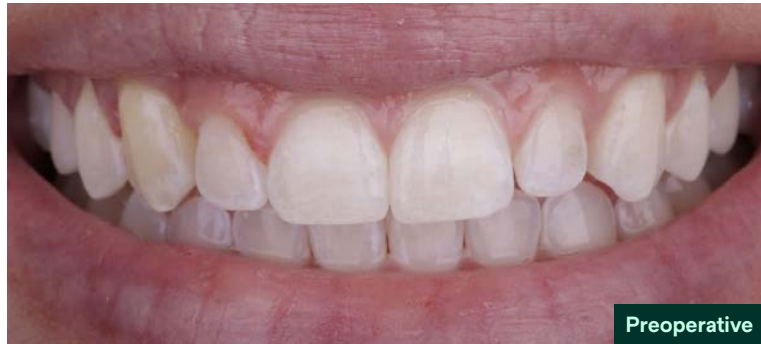
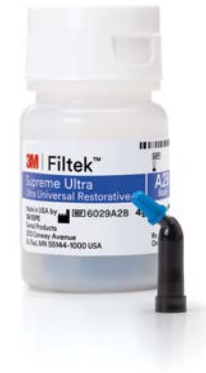Post-orthodontic tooth lengthening (2.5 years post-op)

Teeth restored: #6-11

Clinical case courtesy of Dr. Cappy Sinclair



Featured product:
**3M™ Filtek™ Supreme Ultra
Universal Restorative**
Shades WB & XWE

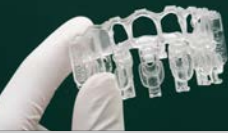

About the case

- Post-orthodontic case treatment
- Patient had issues with the smaller sizes of the laterals and central post-orthodontic treatment
- Filtek Matrix was a great choice given the patient's age and desire to be conservative

Clinical considerations

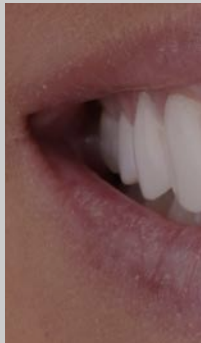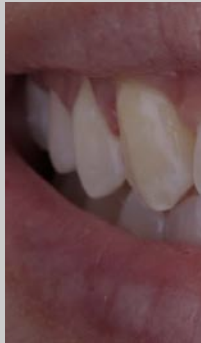- Orthodontic treatment, whitening, gingivectomy, Filtek Supreme Ultra Universal Restorative XWE and WB
- Restorations have held up very well for the current time



Post-orthodontic tooth lengthening (2.5 years post-op)

Teeth re

Clinical case cour



X

Outcome

Post-orthodontic tooth lengthening

The outcome that we achieved was excellent for the starting point.

The patient was thrilled that we were able to deliver a result that was able to be an immediate transformation in a period of about 90 minutes.

Immediate post-op

2.5 years post-op

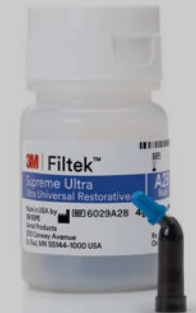About the case

- Post-orthodontic case treatment
- Patient had issues with the smaller sizes of the laterals and central post-orthodontic treatment
- Filtek Matrix was a great choice given the patient's age and desire to be conservative

Clinical considerations

- Orthodontic treatment, whitening, gingivectomy, Filtek Supreme Ultra Universal Restorative XWE and WB
- Restorations have held up very well for the current time

Featured product:
3M™ Filtek™ Supreme Ultra Universal Restorative
 Shades WB & XWE





Solventum Dental Solutions

2510 Conway Avenue East
Maplewood, MN 55144
USA
1-800-634-2249
3M.com/FiltekMatrix

Warranty

3M warrants this product will be free from defects in material and manufacture at the time of purchase. 3M MAKES NO OTHER WARRANTIES INCLUDING ANY IMPLIED WARRANTY OF MERCHANTABILITY OR FITNESS FOR A PARTICULAR PURPOSE. User is responsible for determining the suitability of the product for user's application. If this product is defective within the warranty period, your exclusive remedy and 3M's sole obligation shall be repair or replacement of the 3M product.

Limitation of Liability

Except where prohibited by law, 3M will not be liable for any loss or damage arising from this product, whether direct, indirect, special, incidental or consequential, regardless of the theory asserted, including warranty, contract, negligence or strict liability.

© Solventum 2024. Solventum, the S logo, Clinpro and Filtek are trademarks of Solventum or its affiliates. 3M and the 3M logo are trademarks of 3M. Other trademarks are the property of their respective owners.